# AERO – DIGESTIVE SYMPTOMS IN CERVICAL SPINE DISORDERS- OUR EXPERIENCE

**[1]SHRADDHA JAIN, [2]DEEPSHIKHA CHANDRAVANSHI, [3]SANIKA KALAMBE, [4]SHYAM JUNGADE, [5]SAGAR GAURKAR**

[1] MBBS, MS, PhD, Professor and Head, [2]Junior Resident, [3]Senior resident, [4]Assistant Professor, Department of Otorhinolaryngology and Head and Neck Surgery, Jawahar Lal Nehru Medical College, Datta Meghe Institute of Medical Sciences (Deemed to be University), Sawangi(M), Wardha, Maharashtra, India.
[5]BPTh, MPT, Associate Professor and Head
Department of Community Health Sciences, Ravi Nair Physiotherapy College, Datta Meghe Institute of Medical Sciences (Deemed to be University), Sawangi(M), Wardha, Maharashtra, India.
E-mail:sjain_med@yahoo.co.in

**Abstract -**
**Introduction:**
Dysphagia in elderly could be attributable to a number of etiological causes ranging from neurologic causes like stroke, malignancies, motility disorders, cervical osteophytic compression, changes in cervical spine curvature anddiffuse idiopathic skeletal hyperostosis(DISH).Cervicogenic dysphagia, dysphonia and stridor in elderly are often an underdiagnosed entity in otorhinolaryngology practice.
**Aims and Objectives:**To correlate the occurrence of upper aerodigestive tract symptoms with various cervical spine disorders.
**Methods:**
A retrospectivestudy of 8 patients presenting in otorhinolaryngology OPD or emergency of AVBRH with upper aerodigestive tract symptoms from January 2016 –December 2017.
**Results:**
Dysphagia and odynophagia are the most common otolaryngological manifestation of cervical spine disorders due to anterior osteophytes compressing the pharynx or esophagus or due to change in the curvature of the cervical spine. Other symptoms are dysphonia and dyspnea. The diagnosis is verified by appropriate radiological study. We have measured C2-C7angle by Cobb method and Posterior tangent technique, in dysphagia due to loss of cervical spine lordotic curvature. Treatment is mainly based on a conservative strategy. Manual therapy was beneficial and resulted in improvement in cervical spine curvature with resultant improvement in dysphagia.
**Conclusion**:
Dysphagia is a relatively common symptom of cervical osteophytes and can also occur due to change in cervical spine curvature. DISH or large projecting anterior cervical osteophytes can present with aerodigestive symptoms. Cervicogenic aerodigestive symptoms are only diagnosis of exclusion and when identified, a multidisciplinary approach should be instituted as soon as possible.

**Keywords -** Cervical spine; Lordosis; Dysphagia; Manual therapy; Elderly; Diffuse idiopathic skeletal hyperostosis (DISH); Forestier's disease; Vocal cord immobilization; Stridor.

## I. INTRODUCTION

Cervical spine disorders like cervical spondylosisand diffuse idiopathic skeletal hyperostosis(DISH) affect primarily elderly population and are often an undiagnosed cause of otorhinolaryngological manifestations.[1-6] Neurologic causes like stroke, malignancies and motility disorders are other more commoncauses of swallowing and voice problems.DISH is usually asymptomatic and, therefore latent. [1,2]After excluding these major causes, most casesof dysphagia in elderly are labelled as age related.

Dysphagia and odynophagia are the most common otorhinolaryngological manifestation of cervical spine disorders due to anterior osteophytes compressing the pharynx or esophagus or due to change in the curvature of the cervical spine. [7,8]Scoliosis, kyphosis–lordosis,and other postural disorders of cervical spine have been linked with dysphagia. [9-11]

Other symptoms of cervical spine disorders are dysphonia and dyspnea.[1,5,6]. Dysphagia, dysphonia and dyspnoea in the elderly are usually attributed to commoner known causes like malignancy, diabetes mellitus and neurologic conditions. The role of cervical spine disorders in causation of these otolaryngological symptoms is often neglected among otolaryngologists and many patients with no identifiable cause of vocal cord immobility are considered as idiopathic.

After exhaustive literature search, we could find only few review articles, case reports or case series, which have studied dysphagia or airway problems, in isolated conditions like DISH, or degenerative spine disorders. [2-6]
The present study is probably first such otolaryngology study which has correlated the

occurrence of various aerodigestive symptoms like dysphagia, dysphonia and dyspnoea in patients with different types of cervical spine disorders with their endoscopic findings.

## II. MATERIAL AND METHODS

A retrospectivestudy of 7 patients presenting in otorhinolaryngology OPD or emergency of a rural tertiary hospital of central India, with upper aerodigestive tract symptoms due to cervical spine problems, from January 2016 –December 2017. A detailed otorhinolaryngological examinaton, radiologic investigations in the form of xray neck, fluoroscopy, Computed Tomography (CT) scan,MRI, endoscopic assessment of upper aero-digestive tract were done to rule out intraluminal and extra-luminal causes of dysphagia, airway and voice symptoms. For assessment of the spine curvature, the images of Lateral radiograph of cervical spine were transferred to Scopydoc 8.0.0.22 version software andC2-7 angle measured by Posterior Tangent technique, by drawing angle of intersection of the posterior tangents at C2 and C7 and Cobb angle, the angle formed by the intersection of the perpendiculars. [7, 12, 13]

Treatment was based on conservative strategy comprising of antibiotics, oral or injectable steroids and steroid/ adrenaline nebulization, in most cases. Manual therapy comprising of myofascial release was done in patients with change in cervical spine curvature for treatment of neck muscle spasm. Post treatment endoscopic assessment was done, in all the cases, and radiologic assessment, in cases with change in cervical spine curvature.

## III. RESULTS

Dysphagia and odynophagia were the most common otorhinolaryngological manifestation of cervical spine disorders due to anterior osteophytes compressing the pharynx or esophagus or due to change in the curvature of the cervical spine. (Table 1) Other symptoms weredysphonia and dyspnea due to anterior osteophytes related to degenerative changes of the cervical spine or DISH. The radiography of cervical spine, showed anterior osteophytes and/or loss of cervical lordosis.In DISH, anterior longitudinal ligament calcification could be seen. (Table.1, Fig.1)The osteophytes at C3-C4 level caused only dysphonia and /or dyspnea with stridor.The anterior osteophytes at C4- C6 levels were associated with dysphagia and/or dysphonia and dyspnea.

(Table 1,) In patients with change in cervical spine curvature, it was difficult to negotiate the flexible fibre-optic endoscope, mimicking a malignancy of post-cricoid region and rigid endoscopy was also difficult. Laryngeal endoscopy findings comprised of oedema and congestion of arytenoids, immobility of vocal cords, pooling of secretions and reduced space of pyriform fossa. The C2 – C7 angle by "Posterior tangent measurement technique" (Fig. 2) and "The Cobb angle, (Fig. 3). were 52.47 º and 56.42 º respectively. Most patients responded to treatment based on conservative strategy comprising of antibiotics, oral or injectable steroids and steroid/ adrenaline nebulization, in the form of improvement in dysphagia, odynophagia, dysphonia and breathing difficulty.Vocal cord immobility did not respond to conservative treatment.

Manual therapy comprising of myofascial release was done in patients with change in cervical spine curvature with resultant improvement in dysphagia. Post manual therapy lateral neck radiograph in one of the patients revealed restoration of cervical lordotic curvature and improvement in C2 –C7 angle by "Posterior tangent measurement technique" from 52.47 º (Fig. 2) to 56.68 º (Fig. 4) and in "The Cobb angle, from 56.42 º (Fig.3) to 45.54 º (Fig. 5).

## DISCUSSION

In our study, dysphagia and dysphonia, both were foundto be present, in patients with spine disorders like DISH and degenerative spine disease with anterior osteophytes.Anterior osteophytic compression at C3-C4 level was associated with only dysphonia. Other authors have also observed anterior osteophytes at C4-C6 as more frequent cause of oropharyngeal dysphagia than C3-C4. [14,15] Changes in cervical spine curvature due to muscle spasms can cause isolated swallowing problems and can mimic post cricoid malignancy or stricture.

We have reported first case of dysphagia due to loss of cervical lordosis with measurement of angles of significance, namely C2-C7 angle, by Cobb technique and Posterior Tangent technique. [7]This case was benefitted by manual therapy by myofascial release of neck muscles.

## CONCLUSION

- Cervical spine disorders like degenerative spine diseases and change in cervical spine curvature are common in the elderly and cervicogenic dysphagia and dysphonia should be considered in the differential diagnosis.
- These are only diagnosis of exclusion and when identified, a multidisciplinary approach should be instituted as soon as possible.

## REFERENCES

[1] Jain S, Singh P, Agrawal G, Kumar S, Banode P. Arytenoid sclerosis in diffuse idiopathic skeletal hyperostosis presenting with acute stridor in elderly:Chance or association? J Laryngol Voice. 2016;6:14-7.

[2] Wang J, Chichra A, Koenig S. An unusual cause of acute hypercapneic respiratory failure. Clin Med Insights Circ Respir Pulm Med. 2011;5:81-5.

[3] Umerah BC, Mukherjee BK, Ibekwe O. Cervical spondylosis and dysphagia. J Laryngol Otol. 1981; 95:1179-83.

[4] Kruk-Zagajewska A, Wierzbicka M, Zagierska H. Dysphagia due to diffuse degenerative changes in the cervical spine. Otolaryngol Pol. 1997;51: 517-22.

[5] Akbal A, Kurtaran A, Selcuk B, Gurcan A, Ersoz M, Akyuz M. The development of dysphagia and dysphonia due to anterior cervical osteophytes. Rheumatol Int. 2009;29:331-4.

[6] Maiuri F, Stella L, Sardo L, Buonamassa S. Dysphagia and dyspnea due to an anterior cervical osteophyte. Arch Orthop Trauma Surg. 2002;122: 245-7.

[7] Jungade S, Jain S, Khobragade S, Telang P. Dysphagia in an elderly due to change in cervical spine curvature treated by manual therapy – A diagnostic and therapeutic challenge. Indian J Anat Surg Head Neck Brain. 2018;4:91-93.

[8] Mann NS, Brewer H, Sheth B. Upper esophageal dysphagia due to marked cervical lordosis. J Clin Gastroenterol. 1984;6: 57-60.

[9] Papadopoulou S, Exarchakos G, Beris A, Ploumis A. Dysphagia associated with cervical spine and postural disorders. Dysphagia. 2013;28:469-80.

[10] Howard J M. "Postural and Spinal Disorders: Do They Affect the Normal Swallow?" Research Papers. 2011; Paper 68.

[11] Grgić V. Cervicogenic dysphagia: swallowing difficulties caused by functional and organic disorders of the cervical spine. Lijec Vjesn. 2013;135: 92-9.

[12] Nagata T, Takami T, Yamagata T, Uda T, Naito K, Ohata K. Significant relationship between local angle at fused segmentsand C2-7 angle: Average duration of longer than 20 years after anterior cervical discectomy and fusion. J Craniovertebr Junction Spine. 2011 Jul;2(2):62-6.

[13] Lippa L, Lippa L, Cacciola F. Loss of cervical lordosis: What is the prognosis? J Craniovertebr Junction Spine. 2017 Jan-Mar;8(1):9-14.

[14] Ohki M. Dysphagia due to Diffuse Idiopathic Skeletal Hyperostosis. Case Rep Otolaryngol. 2012;2012:123825.

[15] Pulcherio JO, Velasco CM, Machado RS, Souza WN, Menezes DR. Forestier's disease and its implications in otolaryngology: literature review.

[16] Braz J Otorhinolaryngol. 2014 Apr;80(2):161-6. Review. English, Portuguese.




**Fig.1 Case 1. CT scan of the cervical spine in a case of DISH, showing large anterior osteophytes at C4–C5 (red small arrow) leading to oedematous hypopharynx and laryngeal inlet with calcification of Anterior longitudinal ligament at the D2, D3, D4 and D5 level (yellow arrow)**

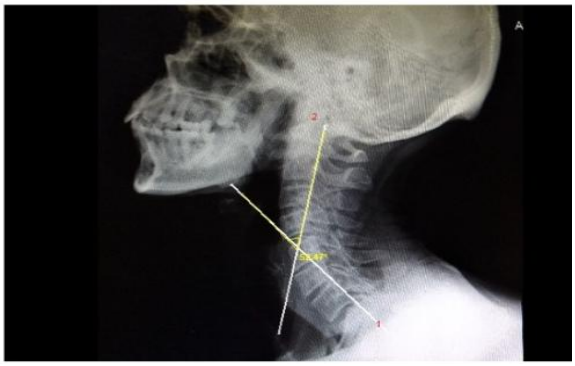

**Fig. 2. Case -4. Pre –treatment measurement of cervical lordosis angle between C-2 and C-7 by "posterior tangent technique".**

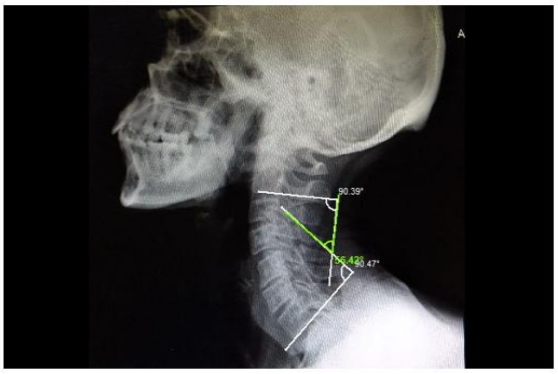

**Fig. 3. Case -4. Pre –treatment measurement of cervical lordosis angle between C-2 and C-7 by "Cobb angle technique".**

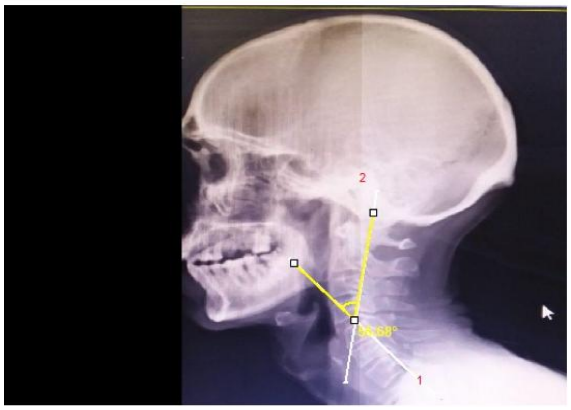

**Fig. 4. Case -4. Post –treatment measurement of cervical lordosis angle between C-2 and C-7 by "posterior tangent technique" showing improvement in cervical lordotic curvature.**

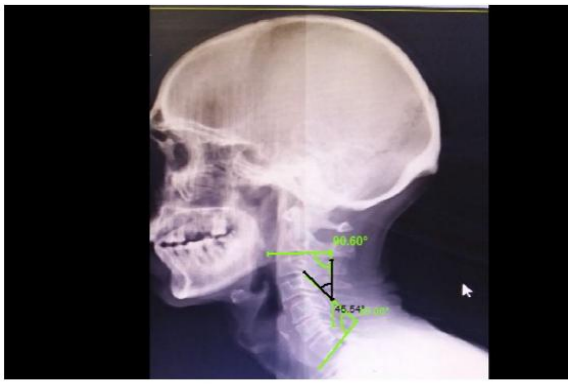

**Fig. 5. Case -4. Post –treatment measurement of cervical lordosis angle between C-2 and C-7 by "Cobb angle technique" showing improvement in cervical lordotic curvature.**

**Table 1**

| | **Dysphagia\ odynophagia** | **Change in voice (Dysphonia)** | **Respiratory distress (Dyspnoea)** | **ENDOSCOPY** | **RADIOGRAPHY** |
|---|---|---|---|---|---|
| **CASE 1** | + | + | + | Left vocal cord fixed in median position with restricted right vocal cord movements<br>Mucosal oedema of both arytenoid. | ***CT neck***---f/s/o DISH, anterior osteophytes at the level of C4-C5.<br>Anterior longitudinal ligament calcification at D2, D3, D4 and D5.<br>B/l arytenoid sclerosis |
| **CASE 2** | + | + | - | Left vocal cord mobility reduced,<br>Crico-arytenoid joint inflammation. | ***Xray cervical spine-***Anterior and posterior osteophytes at C5-C6 level with reduced disc segment. |
| CASE 3 | + | + | - | Left pyriform fossa space reduced.<br>Left Arytenoid edema was present, Bilateral (B/l) vocal cords mobile. | *xray cervical spine-* anterior osteophytes was seen at C4-C5 level. |
| CASE 4 | + | + | - | Pooling of saliva present B/l;congestion of arytenoids present;B/l vocal cords mobile.<br>*Upper GI flexible endoscopy-* scope could not be negotiateddue to post cricoid narrowing.<br>Rigid esophagoscopy was normal.Scope could be introduced with difficulty. | *Barium swallow* – normal<br>*xray cervical spine* –Mild straightening of cervical spine ;anterior osteophytes are seen. |

| | | | | | |
|---|---|---|---|---|---|
| CASE 5 | + | - | - | *UGI endoscopy*- scope could not be negotiated beyond upper esophageal sphincter . | *Xray Cervical Spine*- anterior osteophytes at C4-C5 vertebrae. *Barium swallow* - anterior osteophytes at C4-C5 level . |
| CASE 6 | - | + | - | Left vocal cord fixed in para –median position Congestion and edema of arytenoids | *CT Neck*- anterior osteophytes at C3-C4 level. |
| CASE 7 | + | + | - | Congestion over arytenoids,pooling of saliva present, bilateral vocal cords mobile | *CT Neck*- reversal of cervical lordotic curvature . Anterior osteophytes at C4-C5 level of cervical vertebrae . |