TRANSTHORACIC ULTRASONOGRAPHY ANALYSIS FOR LUNG CANCER DETECTION AND DIAGNOSIS

[1]RUSU-BOTH ROXANA, [2]ACHIM CRISTIAN, [3]DULF EVA-HENRIETTA, [4]CHIRA ROMEO IOAN

[1,2,3]Automation Department, Technical University of Cluj-Napoca, Romania
[4]I[st] Medical Clinic, "Iuliu Hatieganu" University of Medicine and Pharmacy Cluj-Napoca, Romania
E-mail: [1]roxana.both@aut.utcluj.ro, [2]romeochira@yahoo.com

Abstract - Lung cancer (LC) was not common before the 1930s, but increased dramatically over the following decades as tobacco smoking increased, becoming one of the main causes of mortality due to neoplasia, both for men and women. Due to late detection, only 14% of the diagnosed patients are able to survive for a longer period of time (5 years). Once lung cancer begins to cause symptoms, it is usually visible after radiological (X ray) and computed tomography (CT) imaging analysis, or bronchoscopy, investigations invasive to the human body which are performed only based on a doctor's recommendation. An accessible alternative (including bedside exams) with lower costs, no radiation exposure is the transthoracic ultrasonography (US). Nowadays, transthoracic US is underused for lung cancer diagnosis because gray-scale ultrasound images show low contrast and may be hard to interpret by the clinician for an accurate diagnosis even if is proving to be a very useful for the peripheral lung cancers and percutaneous biopsy guiding offering good or even better accuracy, lesser complications compared to the CT guided biopsy. However,driven by the fact that there are few reports that greyscale histogram was previously applied for breast tumors, we aimed to develop a software system for lung cancer detection and diagnosis based on transthoracic ultrasonography using image processing techniques and also neural networks. This application could be of realuse for physicians to identify patients with LC and also could improve the percentages of early detection of lung cancer and the life expectancy of patients by making transthoracic ultrasonography part of the annual checkup exam.

Keywords - Transthoracic ultrasonography, Tumor detection, Lung cancer, Image processing, Neural networks, Software application.

I. INTRODUCTION

At present time, lung cancer (LC) can be considered a leading cause of cancer-related mortality worldwide [1,2], most of the cases being diagnosed in advanced stages. Very low survival at 5 years (15%) of this patients encourage the strategies of improving the current diagnosis techniques. Ultrasonography (US) with its multiple advantages – availability, cost, lack of irradiation -, it is still underused for non-cardiac transthoracic applications as lung pathology. Ultrasonography can assess peripheral lung tumors, offering valuable information related to the tumor structure, vascularization and the parietal invasion. More recently transthoracic US (TUS), US-guided biopsy and other applications (contrast-enhanced US and elastography) have gained a larger field in the management of patients with peripheral pulmonary nodules or masses [3].

Normal ventilated lungs reflect up to 99% of the sound waves. Only the peripheral condensation and lung tumors abutting the visceral pleura can be evaluated by TUS. About 30-35% of the lung cancers are peripheral and can be examined by TUS. If pleural effusions or condensed lung are present, examination of central lesions is possible due to the facilitation of the ultrasound beam.

US examination of the lung is usually performed with convex transducers with frequencies of 3-6 MHz. Normal pleuropulmonary interface is identified as a hyperechoic line situated beneath the chest wall structure, 5-10mm deeper than surface of the ribs. It is mobile with breathing in real time examination which represents the "gliding sign". If a subpleural pulmonary lesion develops, it appears as a hypoechoic image with different shape, structure and contour depending to the type of the disease. Many studies showed the accuracy of the TUS in characterization of the lung tumors [3], comparing this method with computed tomography [4,5,6].

One of the most important problem is the differential diagnosis between benign condensations or tumors and malignant lesions [7]. Main TUS characteristics of a peripheral lung cancer are the following:

- irregular contour of the lung surface, sometimes with spiculation in the adjacent lung (usually regular in benign lesions).
- the shape of the tumor is usually round, (benign condensation being triangular or polygonal)
- the margins of the tumors are sharp delineated from the ventilated lung (benign lesions are usually less sharp delimited from normal ventilated lung).
- small tumors do not contain air, tumoral growth displacing the gas, opposed to benign condensations which possesses air alveolograms and bronchograms. Larger tumor (over 5cm in diameter) can present necrosis, sometimes with fistula in the bronchial three and large central cavities with air.
- destruction of the adjacent lung and parietal wall structure due to invasion on the malignant tumors (condensations are limited to the pleural surface).

Considering this attributes, we developed our criteria for differentiation peripheral lung cancers and benign condensation through image processing analysis of the pathologic changes which can be visualized with TUS. Hence, the main contribution of this work consists in the development of a software system based on our developed differentiation criteria able to accurately and non-invasively help doctors fordifferential diagnosis of lung cancer.

II. METHODOLOGY

The proposed methodology and even the developed differential diagnosis criteriato accurately detect lung cancer was developed based on our previous experience in a previous study aimed to prove the advantages of ultrasonography (US), by performing a comparative evaluation of lung lesions in contact with the thoracic wall by transthoracic US and computed tomography (CT). This study included 131 patients with thoraco-pulmonary peripheral lesions, demonstrated by CT [5,6]. Regarding tumor invasion, intratumoral necrosis and peritumoral atelectasis in patients with thoracic lesions in contact with the thoracic wall [5,6] there is an agreement between the two imaging methods. However, the result of this first study concluded that the US visualization of the lesions provides structural details, being very accurate, bringing important elements for tumor staging which can allow a quick differential diagnosis with other types of lesions proving that US is superior to CT in terms of sensitivity and specificity [6, 8].

The first step consisted in conducting a prospective study involving patients with confirmed diagnosis of primary lung cancer and other thoracic diseases. This step involved the identification and the enrolment in the study of the potential cases, blood sample prelevation, transthoracic ultrasound examination, ultrasound image acquisition. The result of this step consisted in two population of patients, one with peripheral lung cancers and one with lung condensations. The transthoracic US examination was performed using a General Electric LOGIQ S6 equipment for both populations. The ultrasonography images and several parameters likediameters, contour, echogenicity, distribution of the vascularization, invasion of the adjacent structures were recorded for further use in the next step.

The second step was focused of the elaboration of the lung cancer differential diagnosis criteria representing the core in the development of the lung cancer diagnosis software system. It must be mentioned that such a software could be of real help to help physicians to identify patients with LC and differentiate them from benign condensationsenhancing the success of therapy by early detection of cancer, avoid unnecessary biopsies.

To this end, the main features that allow differentiation between lung cancer and other lung diseases were defined and, as presented in the introductory section, are mainly related to the shape of the nodules, the echogenicity of the different regions and the regularity of their contours.

A round shape of the tumor indicates is considered to be malignant finding, benign condensation being triangular or polygonal.

Moreover, when examining the smoothness of the contour, benign lesions are usually less sharp delimited from normal ventilated lung as opposed to a rounded well-defined outline, sharp delineated from the ventilated lung.

This step relied mostly on the on the clinical experience of the physicians. The result of this step consisted in a list of main features, translated in image analysis indexes from medical criteria, that we need to extract from the ultrasonography image in order to be able to help the diagnostic process or even give a probabilistic diagnostic. The defined features were also classified based on their importance in the differential diagnostic procedure: 1) the contour smoothness index; 2) the shape index; 3) the transition rate index of the contour pixel intensities; 4) the whiter spots index inside the contour and 5) the aspect ratio index of the shape contour.

The third step consisted in the development of the differential diagnostic software system. The software system analysis procedure consists of three main steps: image preprocessing and region of interest extraction, tumor features index extraction and lastly the possible diagnostic index evaluation. It must be mentioned that a neural network model was used in order to determine the possible diagnostic index.

III. LC DIGNOSTIC SOFTWARE SYSTEM IMPLEMENTATION

Matlab software environment was used for the development stage of the lung cancer differential diagnostic software system. This software was chosen due to its native image processing capabilities, [9] on top of which we developed our own algorithms to determine the index of the previously determined main features. Plus, it also supports the development of user interfaces which are of outmost importance for physician further use of the diagnostic system. As a requirement it was mandatory to develop a simple graphical user interface, Fig.1, in order to enhance the efficiency and ease of use for the underlying logical design of the program.

The developed user interface allows the user to load an ultrasound image to the diagnostic system and select a region of interest. The region o interest can be defined or redefined by using the mouse/mousepad. The user has also the possibility to place several white lines on the ultrasound image to eliminate the irrelevant areas for the diagnostic system like acoustic shadow that occurs when the ultrasound wave encounters a very echo dense structure like bones that strongly absorb or reflect ultrasonic waves. The user can also adjust another

parameter: the number of iterations that the active contour algorithm should perform to evolve the segmentation process. From our experience 300 iterations should be enough, set also as default value. After the region of interest is defined the user can run the diagnostic system by pressing the Run button. At this point, the results will be presented in the left lower part of the diagnostic system user interface consisting in the main features index values plus the possible diagnostic index in percent.

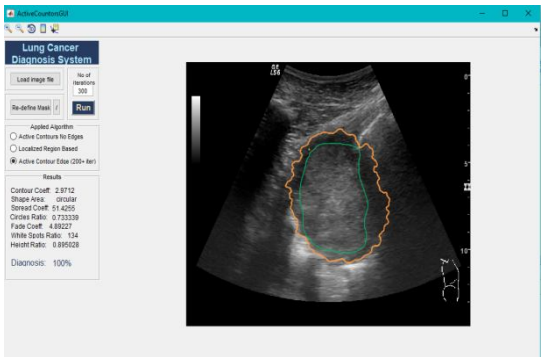

Fig.1 Lung cancer diagnostic system user interface

In order to determine the defined features indexes it is necessary to determine the contour of the tumor as accurate as possible. To this end we implemented an edge-based active contour algorithm which starts from the previously defined region of interest, mask, specified as a binary image, that specifies the contour's initial state, and then actively expands until it finds object boundaries [10 - 13].

After the exact outline of the region of interest obtained by the contour algorithm, several parameters are determined for further use in the feature index values evaluation. Hence, the coordinates of the shape centroid were easily determined from the arithmetic mean of all points in the shape, as well as all the euclidean distances (D) from it to every contour pixel using the equivalent Pythagorean theorem.

D(i)=Dist (CPixelX(i),CPixelY(i),CentreX,CentreY)

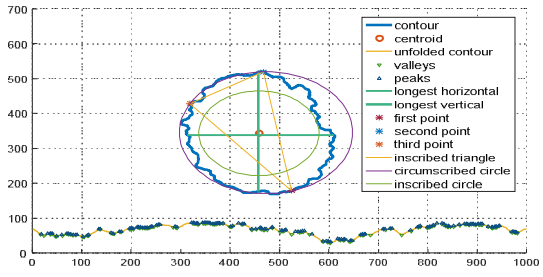

Fig.2 Shape key parameters for lung mass classification

To determine the contour smoothness index, the contour of the tumor was unfolded, Fig.2, and the difference between the peaks (a pixel situated farther from the centroid) and the valleys (a pixel situated closer to the centroid) was computed. The contour index was finally expressed as the mean of all these differences. A mass with a perfectly smooth contour would imply that D(i) would have no fluctuations and the unfolded outline would be a straight line, indicating that the shape of the mass is a circle of radius D.

CSI = mean(abs(difference([peaks; valleys])))

The shape of the mass is very important considering that the shape of the tumor is usually round while benign condensations are usually triangular or polygonal. Hence, in order to determine the shape index value of a mass it was necessary to determine different ratios between the area determined by the contour and the area determined by the circle inscribed in the contour, the circumscribed circle and the inscribed triangle. The difficulty was to determine the contour inscribed triangle for which it was necessary to choose three points on the contour situated the farthest from the centroid to ensure that the area determined by the inscribed triangle is the largest.

The first vertex was determined by evaluating all D(i) distances to choose the contour pixel situated the farthest from the centroid. In order to find the next two vertices, we know that they must be situated relatively opposite to this first vertex and also to each other. Hence, the second vertex must be located on the shape's outline at least sixth of the entire contour length farther, by either side of the first vertex and the third vertex must be at a length/6 minimum distance of each of the other two. The determined vertices were also used to determine the circumscribed circle, while the inscribed circle was determined by using the smallest D(i) as radius.

The ratios were determined: 1) triangle ratio=contour area / triangle area; 2) circumscribed circle ratio=circle area / contour area and 3) inscribed circle ratio=contour area/ circle area. Finally, the shape index value is expressed by the minimum value between these 3 ratios. The circular shape of the mass is indicated if the minimum value is a circle ratio and triangular otherwise.

Another index of high importance is the transition rate index of the contour pixel intensities in the lower part of the mass contour. An indication of the cancerous nature of the mass is given by a hard in depth transition of the pixel intensities.

The developed algorithm to determine the transition rate index consist in evaluation of two different brightness averages considering the pixels around the mass's outline, a border of high contrast in brightness: one based on the intensities of the contour interior pixels and one based on the intensities of the contour exterior pixels around the lower outline. Finally, the transition rate index is determined by the ratio between these two brightness averages. A small value result indicates that the pixel intensities decrease gradually, slower, while a large value resultwill indicate a sudden intensity change.

TRI = (OutAvg/InAvg)

The next index to be determined is the whiter spots index inside the mass contour. White spots are pixel conglomerates situated inside the mass contour with a higher intensity, which indicate, from a medical point of view, the presence of healthier areas inside the mass. A small number of with spots indicates the cancerous nature of the mass. In order to determine the brighter pixels, the intensity of the contour interior pixels is compared to their average intensity. Finally, the whiter spots index will be expressed as a ratio between the cumulative area of the interior with spots and the expanded shape area, so that to include the outline's surroundings for a large intensity range. A small value result will indicate more or larger white spots which infers the presence of healthier areas.

WSI=sum(Img(ROImg>=mean2(ROImg(shape==0)= 0 >0)))

Another important index in determining the nature or the studied mass is the aspect ratio index of the mass contour. It can be determined by the ratio between the transversal and latero-lateral axes in medical terms. This in equivalent to the ratio between the longest vertical line and the longest horizontal line. These two lines were determined by analyzing each pair of opposite pixels and computing the distance between them. The reason behind this aspect ratio index is because the non-cancerous formations, especially pneumonia, typically have a triangular shape with the farthest vertex pointing inwards, as seen in Fig.3. This pathological characteristic implies that the longest horizontal line inside the triangular contour is geometrically situated above the centroid, meaning much closer to the exterior surface of the body.

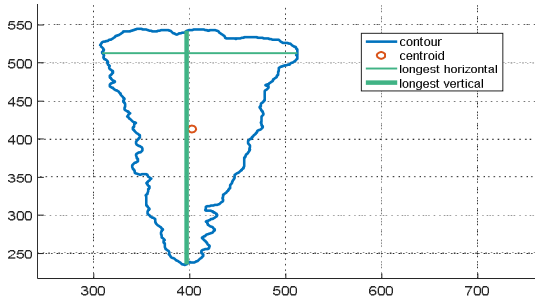

Fig.3 Aspect ratio index evaluation

Once all the feature index algorithms were implemented the final step in the development of the lung cancer diagnostic system was to express possible diagnostic index based on the values of the feature indexes. The chosen approach was to develop an appropriate size neural network, to train it based on the evaluation of all feature indexes on a relatively large set of ultrasound images from both populations considered in this study: one with peripheral lung cancers and one with lung condensations. To this end, we used over 50 such images, to determine the nominal range values for each of the feature indexes, and also to use the values of the indexes as training data for the developed neural network. The neural network was also implemented in Matlab and consists of three layers – input, output and hidden, Fig.4. The number of neurons of the input layer is completely and uniquely determined by the shape of the training data, specifically the number of features in our data. As our desired final result is a probabilistic one, a diagnosis indicating the tendency towards a cancerous nature of the studied area, the output layer uses the softmax function, often used in the final layer of a neural network-based classifier.

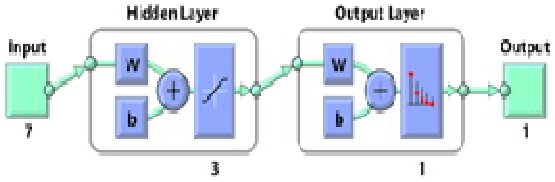

Fig.4 Neural network structure

IV. RESULTS AND DISCUSSION

Once the diagnostic system was developed and the neural network was trained a series of tests were performed to determine the accuracy and degree of lung lesions detection using a new set of 30 ultrasound images of confirmed malignant tumors (cancers) and other non-cancers, as test scenarios.

For the first test scenario the diagnostic system was tested on multiple confirmed cancer ultrasonographies, some results examples being presented in Fig.5.

The mask defined by the user is represented with a green line while the orange contour line was determined by the implemented contour algorithm, Fig.5.a.

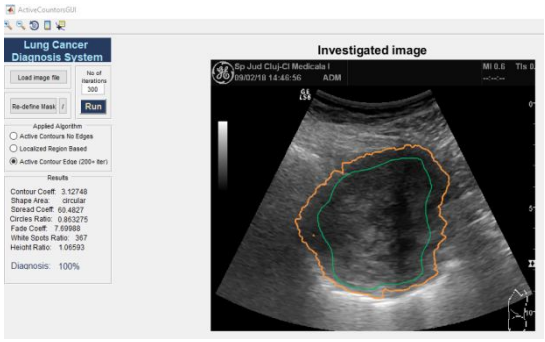

a.

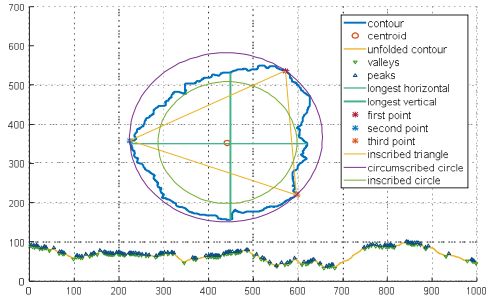

b.

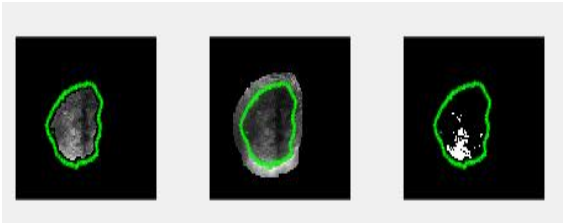

c

Fig.5 Mass classification indexes for necrotic tumor

The diagnostic system also illustrates, Fig.5.b, all the important shape parameters, points and distances used for determining mass classification indexes. Fig.5.c presents the evaluation of the whiter spots index, highlighting the areas inside and around the contour used by the algorithm.Based on the obtained values for the mass classification indexes, the final diagnosis represented by the possible diagnostic index indicates a 100% chance of a malign tumor as the confirmed diagnostic.

As second test scenario the diagnostic system was tested on multiple non-cancer ultrasonographies, some results examples being presented in Fig.6. As in the previous test scenario, the determined contour of the region of interest is represented with orange line, Fig.6.a. In Fig.6.b can be observed that the shape of the region of interest is similar to that of a triangle. Moreover, in this case a large amount of white spots is present inside the determined contour, Fig 6.c. Finally, the possible diagnostic index indicates a 1% chance that the analyzed region of interest is a cancerous formation, in accordance with the confirmed diagnostic.

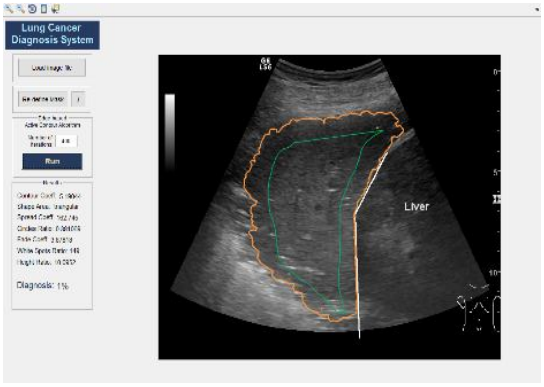

a.

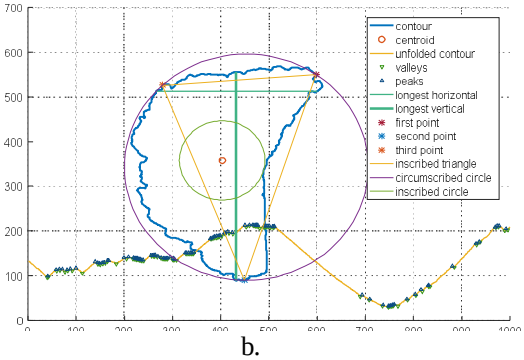

b.

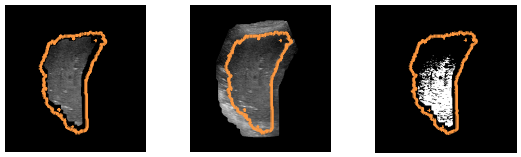

c.

Fig.6. Mass classification indexes for non-cancer lung condensations

By analyzing all the test results it can be stated that the developed lung cancer diagnostic system proved to be effective. The next step is to test it on a larger number of ultrasound images of confirmed malignant tumors (cancers) and other non-cancers and even on the special case of tumors, but at the present time we have no such case in our developed database. By trying to diagnose special case tumors could lead to a new set of diagnostic criteria, new set of shape indexes that will need to be extracted from the lesion contour which we consider for further developments.
As future development we also take into consideration to include blood analysis results in the diagnostic algorithm.

CONCLUSIONS

Transthoracic ultrasonography represents an alternative diagnostic method for lung cancer, being non-invasive, low cost and which can easily be introduced in annual check-ups, having as drawback that the results depend on the physician experience.
The work presented in this paper represents a novel approach for automatic detection and diagnosis of lung tumors based on ultrasound images. The developed diagnostic system can assist young doctors and ultrasound technicians to differentiate and diagnose lung tumors from benign condensations.
The experimental results obtained so far prove the effectiveness of the developed diagnostic system.

ACKNOWLEDGMENTS

This work was supported by a grant of the Romanian National Authority for Scientific Research and Innovation, CNCS – UEFISCDI, project number PN-III-P2-2.1-PED-2016-0425, contract number 178PED/2017.

REFERENCES

[1] DR. Brenner et all., “Previous lung diseases and lung cancer risk: a pooled analysis from the International Lung Cancer Consortium.”, in Am J Epidemiol. 2012 Oct 1;176(7):573-85. Epub 2012 Sep 17.
[2] J. Didkowska, U. Wojciechowska, M. Manczuk, J. Lobaszewski, “Lung cancer epidemiology: contemporary and future challenges worldwide”, in Ann Transl Med. 2016;4(8):150. DOI: 10.21037/atm.2016.03.11
[3] S Sartori, P. Tombesi, “Emerging roles for transthoracic ultrasonography in pulmonary diseases”, World J Radiol. 2010;2(6):203–14. DOI: 10.4329/wjr.v2.i6.203

[4] V Bandi, W Lunn, A Ernst, R. Eberhardt, H Hoffmann, FJ Herth," Ultrasound vs. CT in detecting chest wall invasion by tumor: a prospective study", Chest. 2008;133(4):881–6. DOI: 10.1378/chest.07-1656

[5] R.I. Chira et. all, „Transthoracic Ultrasonography: Advantages and Limitations in the Assessment of Lung Cancer", InTech, 2017

[6] Chira R, Chira A, Mircea PA." Intrathoracic tumors in contact with the chest wall – ultrasonographic and computed tomography comparative evaluation", Medical Ultrasonography 2012; 14 (2): 115-119.

[7] S Beckh, "Neoplastic consolidations in the lung: primary lung tumors and metastases" In: Mathis G, editor. Chest Sonography. 3rd ed: Springer-Verlag Berlin Heidelberg 2011. pp. 69–77. DOI: 10.1007/978-3-642-21247-5

[8] LF. Herbert, "Drawbacks and Limitations of Computed Tomography", in Tex Heart Inst J. 2004; 31(4): 345–348.

[9] L.K.Wee, E. Supriyanto, W. M. H. B. W. Mahmud, "Ultrasound Image Processing: And Its Application Using Matlab", Lap Lambert Academic Publishing GmbH KG, 2011, ISBN 3845417838, 112 pp

[10] V. Caselles, R. Kimmel, G. Sapiro, Geodesic active contours. International Journal of Computer Vision, Volume 22, Issue 1, pp. 61-79, 1997.

[11] F. Boutaouche and N. Benamrane, "Diagnosis of breast leasions using the local Chan-Vese model, hierachical fuzzy partitioning and fuzzy decision tree induction", in Iranian Journal of Fuzzy Systems 2017

[12] S. N. Acho and W. I. D. Rae, „ Dependence of shape-based descriptors and mass segmentation areas on initial contour placement using the chan-vese method on digital mammograms", in Computational and Mathematical Methods in Medicine, 2015, 1-16.

[13] P. Rahmati et. all, "Mammography segmentation with maximum likelihood active contours", in Med. Img. Analysis, 2012, 1167–1186.

★★★