AN IDENTIFICATION METHOD OF NORMAL AND EDEMATOUS HUMERAL HEAD FROM PD WEIGHTED MR IMAGES BASED ON GLCM TEXTURE FEATURES

[1]AYSUN SEZER, [2]HASAN BASRI SEZER, [3]SONGUL ALBAYRAK

[1]Yildiz Technical University, Computer Engineering Department, Istanbul, Turkey
[2]Sisli Hamidiye Etfal Training and Research Hospital, Orthopaedic and Traumatology Clinic, Istanbul, Turkey
Email: aysun@ce.yildiz.edu.tr, songul@ce.yildiz.edu.tr, drhbsezer@gmail.com

Abstract: Bone edema is an important clinical issue that may cause considerable pain. Patients with shoulder pain may have bone edema frequently. Bone edema is detected in PD weighted MR images however presence of bony edema may hamper both visual and automatic segmentation of bone from the PD weighted MR images. The automatical detection of the presence and the distribution of the bone edema may help clinicians to focus on the location and the magnitude of the bone pathology. The objective of this research is to develop a computer aided detection (CAD) system which is capable of recognizing normal and abnormal humeral head images by using texture features derived from gray level co-occurrence matrices (GLCM). In this study GLCM were calculated with using symmetric and non-symmetric matrices which have different displacement and orientation. GLCM matrices were used in Haralick algorithm to extract feature of the region of interest. To verify the performance of the extracted features, we deployed MLP (Multilayer Perceptron), SVM (Support Vector Machine) and KNN (K nearest neighbors) methods and we demonstrated their power in differentiating the normal and abnormal regions. The proposed approach was tested on our own dataset which consists of 79 normal and 91 edematous humeral heads in PD weighted MR images. The resulting classification accuracy produced by the SVM and KNN were 94, 11% and MLP was 93, 52 %. The proposed system is a promising tool for classification of edematous and normal humeral heads from PD weighted MR images.

Keywords: GLCM, image texture analysis, pattern classification, PD weighted MRI

I. INTRODUCTION

Color, shape and texture are important parameters that are taken into account in the identification of an object. Objects with similar color and shape can be identified on the basis of their texture. Image analysis based on the texture requires the knowledge of the pixel characteristics of an image. Texture feature analysis is accepted to be successful in the object classification and segmentation of important regions of a gray level images.

According to the method of extracting image texture features, image texture can be divided into four categories as statistical, structural, model based or transform based. Statistical image texture analysis uses both the original image values (first order statistics) and special relationship between groups of two pixels in the original image (second order statistics) [1][2].

GLCM is widely used both for classification and segmentation purposes [3]. Doyle et al. extracted Haralick features from tissue patches of prostate biopsy specimens. They used SVM to classify the digitalized histology slides with a success rate of 92.4% [4]. Sertel et al. classified neuroblastoma as favorable and unfavorable from the histological specimens by using texture feature extracted using co-occurrence statistics. The overall classification accuracy was 88.4% with KNN classification method [5]. Guang-Ming classified liver tumor patients with utilising the texture feature of B mode ultrasound images by GLCM matrices. He claimed that the proposed FSVM algorithm and GLCM texture feature technique was excellent in ultrasonographic classification of malignant and benign liver tumors with an overall success value of 97% [6]. Huan et al. utilised PET-CT images to plan the radiation treatment of head and neck cancer. They extracted texture feature from GLCM and neighborhood grey tone difference matrices from predetermined ROI. These features were used to classify abnormal tissue from normal with KNN and decision tree based KNN. The sensitivity and specificity were 89% and 99% respectively [7].

In our previous study we automatically segmented both normal and edematous humeral heads from PD weighted MR images [8]. In this study we used previously segmented PD weighted humeral head images to construct image patches. In the first step these image patches were used to compute GLCM at different displacements and orientation. Then GLCM were used in Haralick algorithm to extract features. These features were used as input vector for SVM, KNN, MLP classifiers with purpose of distinguishing and classifying normal and edematous cases.

II. MATERIAL and METHOD

2.1 Image dataset

We included shoulder MR images of 170 patients who have been admitted to a state hospital in Istanbul. The original data set was collected by authors. We used 1.5 Tesla PD weighted MR images. The size of the DICOM image was 256x256 pixels. The slice thickness was 4 millimeters. We grouped patients according to appearance of humeral head as

normal and edematous. The number of the patients were 79 in normal group, 91 in edematous group.

In our previous study we automatically segmented normal and edematous humeral heads from PD weighted MR images with active contour without edge method with a success rate of 92, 25% [8]. Fig. 1a shows a segmented normal humeral head. Fig.1b shows a segmented edematous humeral head in red outlines. Image patches were automatically generated from the segmented humeral heads with bounding box method as shown in Fig. 1a and Fig. 1b.

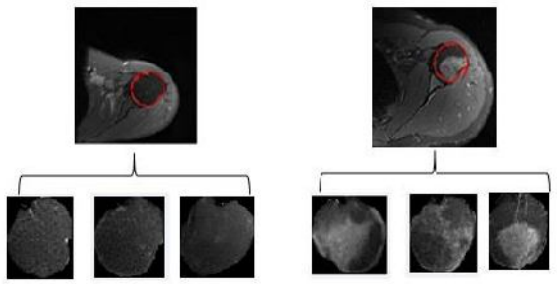

a **b**

Fig.1 a. and b. demonstrates segmented humeral heads and generated image patches from normal and edematous humeral heads respectively.

2.2 Image texture extraction approach

GLCM, is one of the well-known and widely used texture analysis methods and also known as gray tone spatial dependency matrix. GLCM is a frequency matrix which calculates sum of repetition of pair of intensity values in an image in a given displacement (d:distance) and orientation (θ:angle) also named as offset. The GLCM matrix calculates the second order joint conditional probability density function (PDFs) of gray level pairs in an image. Varying offset values will give changing GLCM matrices and different co-occurrence distributions which will result in different image features for the same reference image [9][10].

GLCM of an image is computed using displacement vector d (distance: distance to the adjacent neighbor) and rotational angles (preferably $0o$,$45o$,$90o$ *and* $135o$) (Fig. 2a). An example is given in Fig. 2. In Fig. 2b, image intensity values are given in the form of a matrix. Fig. 2c demonstrates calculated GLCM where (i, j) represents the number of times a point having gray level j occurs relative to a point having gray level i for offset d=1 and $\theta = 0o$.

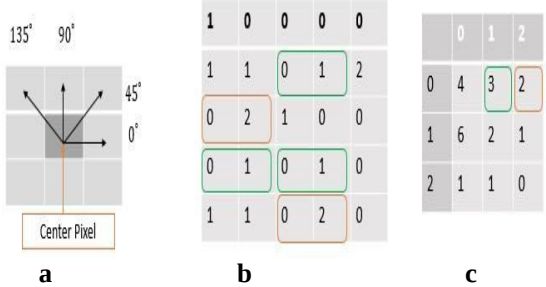

a **b** **c**

Fig.2 a) Different orientations of center pixel used to calculate GLCM (θ: $0o$,$45o$,$90o$ *and* $135o$). b) 5X5 test image intensity values in the form of a matrix c) GLCM matrix calculated by given image in fig2.b for offset d=1 and $\theta = 0o$.

Widely used texture features that can be obtained from GLCM are contrast, energy, homogeneity, correlation and entropy [11]. We calculated also other metrics derived from GLCM as angular second moment (ASM), variance, difference variance, difference entropy, difference moment and two measurements of correlation features . ASM is a measure of homogeneity of an image and energy is a measure of uniformity. ASM and energy are defined as

$$ASM = \sum_{i=0}^{N-1}\sum_{i,j=0}^{N-1} P_{i,j}^{\,2} \qquad Energy = \sqrt{\sum_{i=0}^{N-1}\sum_{i,j=0}^{N-1} P_{i,j}^{\,2}} \qquad (1)$$

$P_{i,j}$ is the GLCM of a given image where N is the number of distinct grey level . μ_i , σ_i are the mean and variance of $P_{i,j}$ respectively. Entropy measures randomness or disorder of an image and indicates complexity of an image. Contrast is a measure of the amount of local variations present in an image. Entropy and contrast are described as follows;

$$Entropy = \sum_{i=0}^{N-1}\sum_{i,j=0}^{N-1} P_{i,j}\left(-\ln P_{i,j}\right), \qquad Contrast = \sum_{i=1}^{N-1}\sum_{j=1}^{N-1} P_{i,j}\,(i,j)^2 \qquad (2)$$

Homogeneity is a measure of amount of homogeneity and correlation is a measure of gray tone linear dependencies in an image. Homogeneity and correlation are defined as

$$Homogeneity = \sum_{i=0}^{N-1}\sum_{j=0}^{N-1} \frac{P_{i,j}}{1+(i,j)^2} \qquad Correlation = \sum_{i=0}^{N-1}\sum_{j=0}^{N-1} P_{i,j}\left(\frac{(i-\mu_i)(j-\mu_i)}{\sigma_i\sigma_j}\right) \qquad (3)$$

GLCM can be calculated from symmetric or non-symmetric matrices. GLCM is defined as symmetric when the neighboring pixel of (i,j) at ($\theta = 0o$) would be equal to pixel of (j,i) at ($\theta = 180o$). In this paper we have computed all of the 13 Haralick's second order features stated above for each of the symmetric and non-symmetric GLCM created at different displacement and orientations (θ1=$0o$,$45o$,$90o$ *and* $135o$ *and* d=1,2,4,8,12,16). For each of the calculated GLCM different features were extracted and used for classification of PD weighted MR images as edematous and normal.

2.3 Classification Methods

In this paper we employed MLP, SVM method and KNN classifier. Feature information gathered from GLCM matrices were given as an input to these three different classifiers to find out the discrimination performance of features in comparisons.

Neural networks have been widely used in medical decision making applications because it is believed that they have great predictive ability to discriminate abnormal from normal [12][13]. Neural networks propose many advantages such as better generalization ability, high performance, and less training data. Training an MLP for classification requires updating the weights iteratively through a gradient descent approach with respect to an error correction strategy. Backpropagation algorithm can be used effectively to train an MLP neural network. MLP can distinguish data that are not linearly separable.

The KNN is a popular algorithm for data classification. The KNN method classifies each sample according to the majority class membership of its K nearest neighbors. The KNN classifier can work effectively even when the data distribution is unknown [14]. First The KNN classifier determines the K closest training samples of the testing sample using the Euclidean distance. Secondly the label of the class that has the majority of the samples among these nearest neighbors is determined as the label of the sample. In this study, KNN classifier was implemented for K= 1, 3 and 5.

Another widely used classifier is SVM which estimates the data classification function. SVM constructs hyperplanes as the decision surface and tries to maximize the margin of separation between normal and abnormal examples [15][13]. SVM method has many advantages such as good ability to handle high dimensional problem and minimum classification structural error. The limitation of this method is that an unbalanced dataset could lead to poor results.

2.4 Validation of the classification methods

We performed the validation of the performance achieved by the proposed method using the rates of accuracy and accuracy of the cross-validation with 10-fold for each prediction to verify the correctness of the created model with all results obtained in the classification step. The accuracy is defined by

$$\frac{TP+TN}{TP+TN+FP+FN} \quad (4)$$

where TP is the number of tissues correctly classified as abnormal, TN is the number of normal tissues correctly classified, FP is the number of abnormal tissues wrongly classified as normal and FN is the number of tissues wrongly classified as abnormal.

III. EXPERIMANTAL RESULTS

GLCM is a matrix which shows how often different combinations of pixel intensity values occur in an image. GLCM matrices were calculated by both symmetrical and non-symmetrical methods at different displacement and orientations. Haralick features were extracted using calculated co-occurrence histograms which are simply the joint frequency of the intensity levels of a pair of pixels with a given spatial relationship.

In our study MLP, SVM and KNN (implemented for K=1, 3 and 5) classification methods were used to classify the extracted Haralick features. The performance of these three different classification methods in classification of the calculated GLCM features were compared for our specific problem which is the differentiation of normal and abnormal humeral heads. In order to evaluate the classifiers with respect to its discriminatory ability, we have estimated accuracy of a predictive model by using 10 fold.

Table 1.Classification results of non-symmetrically extracted GLCM features with different displacement and orientation ($\theta_1 = 0^o, 45^o, 90^o$ *and* 135°).

Displacement	MLP	SVM	KNN 1	KNN 3	KNN 5	AVERAGE
d = 1	90,58	91,76	89,41	89,41	85,29	89,29
d = 2	90,58	91,76	88,23	89,41	87,64	89,524
d = 4	90,58	93,52	89,41	88,82	89,41	90,348
d = 8	92,35	**94,11**	91,17	92,94	92,94	**92,702**
d = 12	91,76	93,52	92,94	91,17	91,76	92,23
d = 16	90	92,94	90,58	92,35	**94,11**	91,996
AVERAGE	90,98	92,94	90,29	90,68	90,19	

Table 2.Classification results of symmetrically extracted GLCM features with different displacement and orientation ($\theta_1 = 0^o$ *and* 180°).

Displacement	MLP	SVM	KNN 1	KNN 3	KNN 5	AVERAGE
d = 4	90,58	92,35	88,82	88,23	88,23	89,642
d = 8	92,35	**94,11**	88,82	91,17	92,35	91,76
d = 12	93,52	94,7	92,94	**94,11**	93,52	**93,758**
d = 16	90	92,94	90,58	92,35	**94,11**	91,996
AVERAGE	91,6125	93,525	90,29	91,465	92,0525	

Table 1. demonstrates the classification results of GLCM features extracted with non-symmetrical method with different displacement and orientation. The performance of the SVM, MLP and KNN (K=3) methods were the highest given the displacement value was 8 with the accuracy rates of 94.11%, 92,35% and 92,94% respectively. The result of KNN (K=1) method was highest given the displacement was 12 with an accuracy rate of 92,94 %. The result of KNN (K=5) method was highest given the displacement was 16 with an accuracy rate of 94,11 %.

Table 2. demonstrates the classification results of GLCM features extracted with symmetrical method. The performance of the SVM was highest given the displacement value was 8. The performance of MLP and KNN (K=3) given the displacement value 12 was maximum.

As the displacement and the orientation changes, the calculated GLCM matrices and features alters for the same image. Each classification algorithm has different success rates for a given displacement and orientation. For an example the classification success of the SVM was the highest for a displacement value of 8 for both symmetrically and non-symmetrically extracted GLCM features. However the classification success of MLP and KNN (K=3) were highest for a displacement value of 8 in table 1 and 12 in table 2.

The average success rates of each of the classification methods was higher for the symmetrically obtained feature data than non-symmetrically obtained feature data. The SVM method was proven to be the most successful and the most suitable method for our problem. The average success rate of MLP method was higher than KNN for both symmetrically and non-symmetrically obtained feature data. However KNN (K=3 and 5) has reached the highest success rate of SVM in some displacement values which

MLP was unable to do. The highest success rate (94,11 %) could be obtained by SVM, KNN(K=3 and 5) for different displacement values with symmetrically obtained data.

IV. DISCUSSION

The segmentation and classification of PD weighted images possesses difficulties because of low signal to noise ratio than other modalities of bone imaging.
MLP, SVM and KNN methods were widely used to classify tissue characteristics in medical specimens. MLP and SVM were the most successful and preferred methods in the literature. We applied these three methods on our database composed of edematous humeral heads. The SVM method had good performance for distinguishing normal and abnormal bone. The average success rates of all three methods were higher for symmetrically obtained feature data than non-symmetrically obtained data.

CONCLUSION

In this study we verified that features obtained from GLCM and Haralick methods can be used to classify bone tissue as edematous and normal with high success rates. This is the first study of classification of the humeral head from PD weighted MR images in the literature. The segmentation of humeral head from PD weighted MR images was studied as the first step of this study by the same authors. As we studied on our own database there is no comparable database or study present.

REFERENCES

[1] M.H. Bharati , J.J Liu, J.F MacGregor, " Image texture analysis: methods and comparisons". Chemometrics and Intelligent Laboratory Systems 72, 57–71, 2004.

[2]C. E., Honeycutt, & Plotnick, R. " Image analysis techniques and gray-level co- occurrence matrices (GLCM) for calculating bioturbation indices and characterizing biogenic sedimentary structures." Computers & Geosciences, 34, 1461–1472, 2008.

[3] H.Y Chai, L.K Wee, TT. Swee, S. Hussain," GLCM based adaptive crossed reconstructed (ACR) k-mean clustering hand bone segmentation." Book GLCM based adaptive crossed reconstructed (ACR) k-mean clustering hand bone segmentation City: World Scientific and Engineering Academy and Society (WSEAS); pp. 192-197, 2011.

[4] S. Doyle, M. Hwang, K. Shah, A. Madabhushi, M. Feldman, and J. Tomaszeweski, "Automated grading of prostate cancer using architectural and textural image features," in ISBI, pp. 1284–1287, 2007.

[5] O. Sertel, J. Kong, H. Shimada, U. Catalyurek, J. Saltz, and M. N.Gurcan, "Computer-aided prognosis of neuroblastoma on whole-slide images: Classification of stromal development," Pattern Recognit., vol. 42, pp. 1093–1103, 2009.

[6] G. Xian."An identification method of malignant and benign liver tumors from ultrasonography based on GLCM texture features and fuzzy SVM." Expert Syst. Appl.37, 6737–6741, 2010.

[7] H. Yu, C. Caldwell, K. Mah, D. Mozeg, "Coregistered FDG PET/CT-based textural characterization of head and neck cancer for radiation treatment planning", IEEE Transactions on Medical Imaging 28 374–383, 2009.

[8] A. Sezer, H.B. Sezer and S. Albayrak. Segmentation of humeral head from axial proton density weighted shoulder MRI. 10th International Symposium on Medical Information Processing and Analysis, 2004

[9] R.M. Haralick, K. Shangmugam, I. Dinstein, "Textural feature for image classification", IEEE Trans. Syst. Man Cybern. SMC-3 (6) (1973) 610–621

[10] A. Porebski, N. Vandenbroucke and L. Macaire." Neighborhood and Haralick feature extraction for color texture analysis". In Proceeding of the 4th European Conference on Colour in Graphics, Image and Vision
(CGIV'08), Terrassa, Spain, 316-321, 2008.

[11] G. Beliakov, James, S. and Troiano, L. "Texture Recognition by Using GLCM and Various Aggregation Functions", IEEE International Conference on Computational Intelligence, 1472-1476, 2008.

[12] B. Li, MQ-H. Meng, "Computer aided detection of bleeding regions in capsule endoscopy images". IEEE Transactions on Biomedical Engineering, 56(4):1032–9, 2009.

[13] B. Li and M. Q. Meng, "Texture analysis for ulcer detection in capsule endoscopy images,"Image and Vision Computing, vol. 27, no. 9, pp. 1336–1342, 2009.

[14] D. Schinagl et al., "Comparison of five segmentation tools for F-fluoro-deoxyglucose-positron emission tomography-based target volume denition in head and neck," Int. J. Radiat. Oncol. Biol. Phys., vol. 69, pp. 1282–1289, 2007

[15] G. B. Junior, A. Cardoso de Paiva., A. C. Silva, "Classification of breast tissues using moran's index and geary's coefficient as texture signatures and SVM". Computers in Biology and Medicine, 39 (12), 1063–1072, 2009.

★★★