# A PLATFORM DESIGN FOR ACUTE STROKE ISCHEMIA BRAIN DETECTION IN MAGNETIC RESONANCE IMAGING

**[1]FATHIA ABOUDI, [2]SALAM LABIDI, [3]AYMEN MOUELHI**

[1,2]UTM, High Institute of Medical Technology in Tunisia (ISTMT), LRBTM Research Laboratory of Biophysics and Medical Technology, 9 Avenue Zouheir Essafi 1006 Tunis.
[3]Laboratory of Signal Image and Energy Mastery, ENSIT-University of Tunis, Tunisia., University of Tunis, 5 Av. Taha Hussein, 1008, Tunis, Tunisia.
E-mail: [1]aboudifathia16@gmail.com, [2]labidisalam@yahoo.fr, [3]aymen_mouelhi@yahoo.fr

**Abstract** - Public health is one of the major concerns at the international level. Stroke is an acute cerebral vascular disease, which is likely to cause long-term disabilities and death. Every year, 12 million people are affected by stroke brain in worldwide and the value is increasing. Acute ischemia lesions occur in most stroke patients. These lesions are treatable under accurate diagnosis and treatments. Brain Magnetic Resonance Imaging (MRI) brain is one of the essential non-invasive modalities for the diagnostic of this diseases. Indeed, diffusion weighted (DW) and perfusion weighted (PW) imaging are very helpful to detect acute stroke in early stages. This is a survery paper which presents a platform design of an automated segmentation using benchmark methods (Fuzzy C-Means (FCM), Otsu, Regions growing and Spatial FCM) in order to obtain a robust, rapid, efficient and precocious system detection of acute stroke lesions from MR images obtained from diffusion-weighted imaging (DWI) and perfusion-weighted imaging (PWI). The validation purposes was performed by comparing resulting segmentation to the manual contours traced by an expert. Results show that the SFCM appeared in the plateform is efficient in detection of acute with a accuracy value of 99.1% in PWI-MTT and of 47.44% in DWI and an timing average about one second.

**Keywords -** Brain MRI, Acute Stroke Ischemia Brain, Automatic Segmentation, FCM, SFCM, Diffusion Weight Imaging, Perfusion Weight Imaging, Neuroimaging.

## I. INTRODUCTION

Stroke is a mojor cause of death and disability in both the more developed and the less developed world. Stroke consumes an important part of the total healthcare costs in Europe and the USA [1]. The stroke brain can be placed into two categories an ischemia (cerebral infarction 80%) and a hemorrhage (20%) [2].

Ischemia is a physiological term indicating insufficient blood flow for normal cellular function. In ischemic stroke an obstruction of the cerebral blood supply causes tissue hypoxia, and advancing tissue death over the next hours, which deprives brain cells of oxygen and nutrients. Also the blood flow disturbances often originate from an embolism physically obstructing a cerebral artery or arteriole causing a critical reduction of blood flow to specific parts of the brain [3].

With a statistic values delivered by Pascale REISSER and confirmed by Dr Eric Revue, globally, every years, 12 million people are affected by stroke brain in worldwide, that means one 1 person every 5 seconds, in Europe 1 400 000 , In France, 155 000 new people so one every four minutes and 62 000 will die [4]. In Tunisia, it is the first cause of physical disability in adults and the third cause of death. The average incidence around of 10,000 new people per year but the numbers are increasing, as it was declared by the Huffpost Tunisia [5]. The WHO is talking about a pandemic and is projecting an increase in the incidence of stroke: 23 million in 2030 (for memory 16 million in 2005) [4].

Brain Magnetic Resonance Imaging (MRI) has a high sensitivity for the acute ischemic lesions. It is often used to assess the presence of stroke lesion, her location, extent, age and other factors as this modality is highly sensitive for many of the critical tissue changes observed in acute stroke. Diffusion weighted (DW) and perfusion weighted (PW) MR imaging have been shown to detect acute stroke in early states. DWI measures self-diffusion of water molecules in a tissue. During ischemia, it is believed that cell breakdown impedes movement of water molecules, resulting in increased DWI signal. Lesions appear bright (high signal) on DWI. PWI allows for imaging of micro vascular hemodynamic. Therefore perfusion is normally measured in terms of flow, volume and mean transit time (MTT). Stroke lesions are typically identifiable as region in imaging pondération in MTT.

Time consuming task, taking up to 15 minutes per case with low inter-rater agreement [2]. Developing automated methods that locate, segment, and quantify the stroke lesion area from MRI scans remains an open challenge. Suitable image processing algorithms can be expected to have a broad impact by supporting the clinician's decisions

and render their predictions more robust and reproducible.

We have developed an automatic plateform of detection tool based on fast and reliable segmentation using a particular type of DWI and PWI. In this work, we correlate our automated plateform of segmentation across different DWI maps (b0, ADC) and with PWI maps (MTT) with retrospective manual analysis done by expert in neuroimaging.

## II. RELATED WORK

Acute stroke brain segmentation is one of the major issues in biomedical image processing due to detect precociously the disease. Getting an overview of segmentation techniques for manual segmentation of images, we have found that several methods have been developed using thresholding techniques, clustering and region growing.

Ischemic stroke lesions in MR imaging are difficult to segment for various reasons, which include especially shape complexity and ambiguity. Creating and evaluating automatic methods for segmenting such lesions is difficult because ground-truth is elusive and stroke lesions are widely varied. In addition, accurate segmentation of stroke lesions requires anatomical knowledge. In particular changes in MR images due to ischemic stroke follow the vascular territory of the occluded blood vessel, which is characteristic of cerebrovascular disease and helps in differentiating it from other disease entities. As a matter of fact, in the literature devoted to the segmentation of brain lesions, there has been few works done in the area of multimodal stroke segmentation [6]. Most of the work related concentrated on the detection of tumors [7, 8] and multiple sclerosis lesions [1]. Since 2012 many research are published.

In the brain tumor segmentation (BRATS) challenges held in 2016, the dataset contains a number of subjects with gliomas and the task is to develop automatic algorithms to segment the whole tumor, the tumor core and the Gdenhanced tumor core based on multi-modal MR images. In the latest competition [9], over half of the methods were based on deep neural networks and they achieved top results. For instance, the hyperlocal features (original input image) are used prior to the final segmentation to improve the accuracy [10]. As a pixel-level segmentation problem, there are much more non-tumor pixels than the ones belong to part of the tumors, which means there is a significant label imbalance. To alleviate the imbalance, Lun and Hsu proposed a re-weighted loss function [11]. Randhawa and al also modified the cross-entropy loss function so that the segmentations at tumor edges could be improved [12].

Instead of analyzing multi-modal MRIs in 2D, the Deep Medic approach performs segmentation of tumors in 3D while using extended residual connections [13]. In addition to deep learning algorithms, machine learning approaches based on the random forests [14] also demonstrate good performance using hand-crafted features. The segmentation of sub-acute ischemic stroke lesion is one of the tasks in Ischemic Stroke lesion segmentation (ISLES), which attracted many entries [2]. The challenge is to automatically segment sub-acute ischemic stroke lesions based on multi-modal MR images. Compared with the dataset in the BRATS, the dataset used in the ISLES is smaller. Similar to brain tumors, sub-acute ischemic stroke lesions are difficult to segment [14]. This is because in medical imaging there are a limited number of images with labels available for training. To explore the distinctive lesion features, specific domain knowledge is still helpful.

## III. METHODS AND MATERIALS

**Patient database:**

The MRI brain images are acquired from the service of neuroimaging in the national institute of neurology Mongi Ben Hmida in Tunisia. 17 patients (11 M, 6F, Age: between 17 and 87 years, body weight 53 and 103 kg) referred to our institute for suspected acute stroke and two patients are a reference. Every patients simulated by 71 sequences. All MRI datasets were acquired on a 3 T of Siemens deposed. The MRI images are in DICOM format (Digital Imaging and Communications in Medicine).

**DWI imaging protocol acquisition:** Axial DWI trace images were acquired using a SE_EPI sequence, TE=109 ms, TR=5400ms, FA=90°, NEX=2, 192x192 matrix, b=0 s/ $mm^2$ and a b= 1000 s/ $mm^2$ , FOV= 240x240 $mm^2$ and slice thickness= 3.5 -7mm.

**PWI imaging protocol acquisition:** after injection an intravenous bolus of paramagnetic contrast agent, Gadodiamide, the PWI trace images were acquired using a GE_EPI sequence, TE=45 ms, TR=2780ms, FA=90°, NEX=2, 128x128 matrix , FOV= 240x240 $mm^2$ and slice thickness=5 -7mm.

**Simulation:** We used Matlab R2014a image processing toolbox for simulatioon of segmentation.

## IV. APPROACH

Ischemic stroke segmentation is separating hyperintensed region from brain image. DWI images were processed directly following acquisition. Trends have shown, it being performed by experts, which is

a critical task. Although assessment is performed precisely and with accuracy but this often gets difficult for them and will never be 100% accurate. More ever, radiologist's mental health, if not stable, can result adversely. So, some automated stroke segmentation method is required.

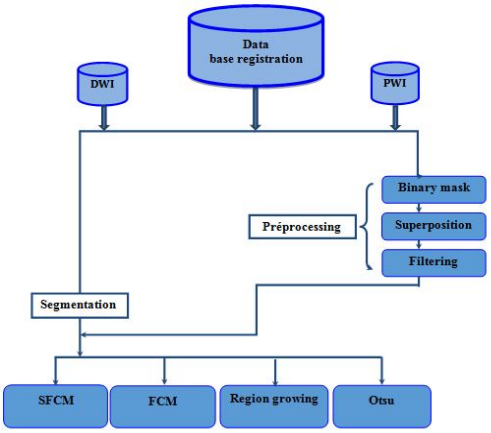


**Fig 1: brain ischemic stroke segmentation approach**

Figure 1 shows approach which is required to be followed in all kinds of segmentation methods used by the interface design. Medically, ischemic stroke region is of great importance as it provides concerned information like which region of brain and by how much percent it is affected and how much more clinically required features. Extracting useful information from multidimensional images is a vital task in medical images segmentation. Thus, accuracy of clinical information depends upon location region precisely, which will help for treatment by formulating right methodology as soon as it is diagnosed.

Many researchers from medical imaging and artificial intelligence field contributed in segmentation by proposing various approaches which were discussed briefly and are grouped under various well known, major segmentation methods [19].

## V. IMAGE PROCESSING /SEGMENTATION

DW images were processed directly following acquisition. The acquired dynamic perfusion images were processed to create perfusion maps (rCBF, rCBV, MTT). MTT maps were chosen for analysis.The DW and MTT images were processed as described in the flow chart in figure 2.

### A. Program implementation:

**Loading and preparing data for processing:**

Diffusion weighted imaging (DWI) images dit not require any pre-processing prior to segmentation. However before performing the segmentation, the MTT data issues of perfusion weighted imaging (PWI) posted by pre-precessing.

**Pre-processing of the MTT data:**

The steps of pre-processing of the PWI-MTT images for segmentation of acute stroke are summarized as follows:




**Fig 2: Steps of pre-processing of PWI-MTT images.**

In this work, we will firstly knows the characteristics of images for segmentation. After, all negative values in the image were set to zero. The non-zero error codes produced in the MTT maps were assigned maximum MTT values on the assumption that poor perfusion (largeMTT, low or no flow) caused the error in those pixels (Fig. 2, steps 2–3). Although the lesion is visible at step 3, the MTT maps were still very noisy and did not provide a clear lesion boundary. Therefore, the MTT maps were also smoothed and de- speckled slice by slice using in finally a 2Dmedian filter (8×8 kernel) (Fig 2, step 4). Our objective was to build a tool n that would segment acute stroke brain lesions on DWI and PWI, images of MRI modalities, semi-automatically and with a minimal timing.

### B. Methods of segmentation:

**Methods of clustering:**

**Fuzzy C-Means (FCM):**

The Fuzzy C-Means (FCM) algorithm is a fuzzy clustering method based on the minimization of a quadratic criterion where clusters are represented by their respective centers. In the case of image segmentation, it assigns pixels to each category by using fuzzy membership functions. The FCM algorithm was proposed by Dunn (1973) and later improved by Bezdek [15]. Let $\mathbf{X}=\{\mathbf{x}_1, \mathbf{x}_2, \ldots,\mathbf{x}_N\}$ denotes an image with N pixels to be partitioned into C clusters or regions. The algorithm allows

partitioning the pixels by iteratively calculating the centers of clusters, $\mathbf{v}_i$ and the membership matrix, **U** through minimizing an objective function, J with respect to these cluster centers and membership values as
follows:

$$J = \sum_{i=1}^{nc} \sum_{j=1}^{n*m} (\mu_{ij})^m \| x_j - v_i \|^2 \quad \textbf{(1)}$$

where, xj and the ith cluster center, $v_i$, m is any real number greater than 1, $\mu_{ij}$ is the degree of fuzzy membership of pixel $\mathbf{x}_j$ to the ith cluster. The objective function is minimized when the large membership values are assigned to the input pixels that are close to their nearest cluster centers and low membership values are assigned when they are far from the cluster centers [16].

**Spatial Fuzzy C-Means (SFCM):**

Although FCM works well in many real-world applications, it can't be applied to deal with spatial data directly, because there are two types of features in spatial clustering problems. The first type of features is regular feature, which refers to ordinary property of non-spatial data. Such typical features are age, income, and et al. The other type of features is directly referenced to a location of the earth, such as Latitude and Longitude. They can be represented by coordinates or vectors. In many features applications, researchers may ignore the specialty of spatial features, and just use traditional clustering algorithms by regarding spatial features as regular features. However, it may unavoidably lead to the loss of some characters of samples and the spatial structures among samples. To solve this problem, some researchers devote to the design of spatial clustering algorithms [17].

**Thresholding based methods:**

The thresholding technique is the simplest method used in the segmentation process. The process collects all the pixels with a certain threshold and rejects other pixels which have values less than the threshold. After the thresholding procedure is applied the stroke region will be isolated from the brain tissue. The stroke regions will be more clearly visible in the output images [18].

Threshold values can either be local or global. There can be multiple individual thresholds or multilevel thresholding segmentation. Global thresholding is the oldest and the simplest process amongst all methods but it cannot justify all variations in an image as threshold value is determined by considering properties of whole image. There can be variations within the object which can be diagnosed through local threshold method. This is an adaptive method which is
used when threshold value is not determined from a part of an image. It can be defined as an operation that involves tests against the function T:

$$T = T\left[\left(\vec{x}\right), p\left(\vec{x}\right), f\left(\vec{x}\right)\right] \quad \textbf{(2)}$$

where x, is the spatial position of image point, p(x) is a local neighborhood property, f(x) is gray level intensity [18]. Thresholding plays with region by including background unwanted pixels and ignoring required regional pixels and situation gets worse in case of noise. It is a well-defined method for images with homogeneous intensity and contrasting region of interest. Its results are questionable with large statistical variations. Hence cannot be used for defining an automatic segmentation method alone.
Otsu's method is used to find optimal threshold value by focusing on maximizing gray level variance and relieves from problem of determining normal distribution parameters. Thus it is widely acceptable threshold determining method [19].

**Region based methods:**

The region growing is a step that groups the pixels or sub-regions into larger regions based on a predefined criteria for growth. A "Region" forms pixels growing with the same intensity level which is used to calculate the area of white mater for the skull [18]. The first step in region growing is to select a set of seed points. Seed point selection is based on some user criterion the initial region begins as the exact location of these seeds. The regions are then grown from these seed points to adjacent points depending on a region membership criterion. Region growing methods can correctly separate the regions that have the same properties we define. And also they can provide the original images which have clear edges with good segmentation results [18].
The concept is simple. We only need a small numbers of seed point to represent the property we want, then grow the region. We can determine the seed point and the criteria we want to make and choose multiple criteria at the same time. It performs well with respect to noise. Also region growing is considered a semi automated method for segmentation because it needed an operator for choise the initial region.

Results obtained after applying the segmentation method with diffusion weighted imaging (DWI) and perfusion weighted imaging (PWI-MTT). The results of image simulation of all the methods have been presented in table 1.

Everyone have properly advantages and disadvantages.

| Sequence / Segmentation Methods | DWI | PWI-MTT | |
|---|---|---|---|
| |  |  |  |
| Threshold Otsu |  |  | |
| Region Growing |  |  | |
| Fuzzy-C-Means (FCM) |  |  | |
| Spatial Fuzzy C-Means(SFCM) |  |  | |

**Table 1: Result of segmentation methods with DWI and PWI-MTT**

## VI. INTERFACE DESIGN

We created an interface of detection of acute stroke brain that we were implanted the methods of segmentation detailed in the precedent paragraph. The access of the interface design is shown in figure 3.




**Figure 3 : the window of access the interface design.**

In order to facilitate the work of clinicians, we have developed a platform with Matlab R2014a coding for the detection of acute stroke. This platform allows access to the different automatic segmentation methods proposed.

We have activated two automatic access keys, one "Cancel", and the other "Go", to go the service platform. When we activates the access windows, the button "Help" allows the visualization of a data sheet for understanding our platform.

This plateform design allows realising the pre-processing steps.

Before moving to the segmentation stage, the clinician must set the cluster number. To perform the segmentation, the clinician must select one of the following buttons: "FCM", "Otsu", "SFCM" and "region growing". The "log out" button allows you to exit the platform. To perform another test, simply restart the platform again, by pressing the button"back" .

Figure 4 demonstrated the activate window of this interface design of detection.




**Figure 4 : the activate window of the interface design.**

## VII. EVALUATION AND DISCUSS

To demonstrate the efficiency of the proposed segmentation strategy, we compared our method with comparable methods from the published literature and with manual methods.

The performance of the methods segmentation in platform design is further compared with the other classification methods by testing the entire techniques on the validation image dataset. A quantitative measure is used to provide the difference between the true regions Ma (constructed by experts in the National Institute of Neurology Mongi Ben Hmida Tunisia) and the classification results Ca [20]. The segmentation accuracy is estimated as:

$$Accuracy = 100 * \left[ 1 - \left( \frac{\left[ A(Ca) \bigcup A(Ma) \right] + \left[ A(Ca) \bigcap A(Ma) \right]}{\left[ A(Ca) \bigcup A(Ma) \right]} \right) \right] \quad (3)$$

Where A (Ca) and A (Ma) are the areas of segmented regions Ma and Ca.

The accuracy and the value timing of all the methods have been presented in the table 2 and the histogram below.

| Evaluation | Segmentation methods | | | |
|---|---|---|---|---|
| | SFCM | OTSU | FCM | Region Growing |
| Accuracy of DWI(%) | 47,45 | 25,40 | 19,33 | 17,40 |
| Accuracuy of PWI-MTT(%) | 99,10 | 62,20 | 62,20 | 71,30 |
| Timing of DWI(s) | 1,22 | 0,64 | 1,09 | 4,68 |
| Timing of PWI-MTT(s) | 0,09 | 0,72 | 0.97 | 5.24 |

**Table 2: Evaluation of segmentation methods using a DWI and a PWI-MTT.**

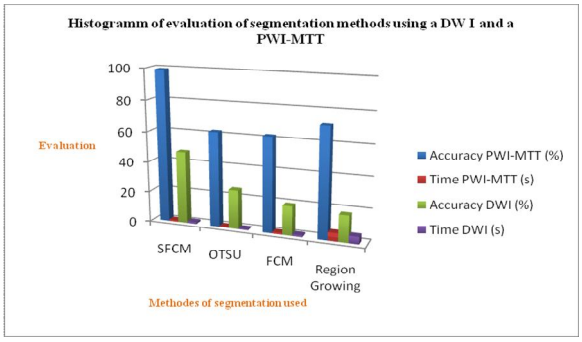


Although SFCM can obtain more reasonable results compared with traditional FCM, there are still some short comings in this algorithm.

## CONCLUSION

In this paper, we presented an interface design of segmentation approaches for acute stroke brain disease based on automatic thresholding, clustering and region based methods. The results were very convincing and encouraging. This will allows us to continue the research in this interested field and try to improve the database with more images. From this study, SFCM approach provide efficient results compared to the other methods in terms of segmentation accuracy (accuracy rate is 99.10% in PWI-MTT). Besides, it takes a reasonable processing time in the case of DWI (less than one second).

## REFERENCES


[1] Y.Kabir, M.Dojat, B.Scherrer, F.Forbes and C.Garbay: Multimodal MRI segmentation of ischemic stroke lesions: Proceedings of the 29 th Annual International Conference of the IEEE EMBS in Lyon (August 2007), p.1.

[2] O.Maier, B.H.Menzeh, J. Gablentz, L. Hani, Rangarajan, S.M.S.Reza and al: ISLES 2015 - A public evaluation benchmark for ischemic stroke lesion segmentation from multi spectral MRI: Preprint submitted to Medical Image Analysis (May 2016), p.2.

[3] M.J.R.J.Bouts: Prediction of tissue outcome after experimental stroke using MRI-based algorithms: PhD thesis, Utrecht University: ISBN: 978-90-393-5955-6. (2013), p.64-65.

[4] P.Reisser, E.Revue: cours IFSI: Institut de formation de soin infirmiers: Journée européenne de l'AVC 2017. https://www.infirmiers.com/etudiants-en-ifsi/cours/cours-neurologie-accident-vasculaire-cerebral.html.

[5] C.Ben Hmida: la champagne de sensibilisation sur l'accident vasculaire cerebral: Huffpost Tunisie (2016).

[6] J.Weinman: Nonlinear diffusion scale-space and fast marching level sets for segmentation of MR imagery and volume estimation of stroke lesions: MICCAI 2003, LNCS 2879, pp. 496–504, 2003.

[7] M. Prastawa , E.Bullitt, S.Ho, G.Gerig, :A brain tumor segmentation framework based on outlier detection: Medical Image Analysis18(3): 217–231, 2004.

[8] S. Capelle: Evidential segmentation scheme of multi-echo MR images for the detection of brain tumors using neighbourhood information. : Information Fusion, 5:203–216, 2004.

[9] B.Menze, A.A. Jakab, S.S. Bauer, J. Kalpathy-Cramer, K.K.Farahani, J. Kirby and al., 2015: The multimodal brain tumor image segmentation benchmark (BRATS]: IEEE Trans, Med imaging (2015), p.34.

[10] P.D.P.D. Chang: Fully convolutional neural networks with hyperlocal features for brain tumor segmentation. In: Proceedings of MICCAI-BRATS 2016 Multimodal Brain Tumor Image Segmentation Benchmark: Change Detection, (2016), p. 4–9.

[11] T.K.T.K .Lun, W.W.Hsu: Brain tumor segmentation using deep convolutional neural network. In: Proceedings of MICCAI-BRATS 2016 Multimodal Brain Tumor Image Segmentation Benchmark: :Change Detection : (2016), pp. 26–29.

[12] R.R Randhawa, A.A.Modi, P.P. Jain, And P.P.Warier: Improving segment boundary classification for brain tumor segmentation and longitudinal disease progression. In: Proceedings of MICCAI-BRATS 2016 Multimodal Brain Tumor Image Segmentation Benchmark: Change Detection: (2016), pp. 53–56.

[13] K...Kamnitsas, E.. Ferrante, S. Parisot, C Ledig, A. Nori, A. Criminisi, D.Rueckert, B. Glocker, :Deepmedic on brain tumor segmentation. In: Proceedings of MICCAI-BRATS Multimodal Brain Tumor Image Segmentation Benchmark: Change Detection (2016), pp. 18–22.

[14] L. Chena, P. Bentley, D.Rueckert: Fully automatic acute ischemic lesion segmentation in DWI using convolutional neural networks: NeuroImage: Clinical (2017), p3.
[15] J. C Bezdek, "Pattern recognition with fuzzy objective function algorithms", Kluwer academic publishers, Norwell, MA, USA, 1981.
[16] S.K.Adhikari , J.M.Sing, D.K.Basu, and M.Nasipuri: A Spatial fuzzy c-means algorithm with application to MRI image segmentation: chapter IEEE (2015),p 2.
[17] Y.Guo, K.Liu, Q.Wu, Q.H and H.Z: A new spatial fuzzy-c means for spatial clustering: Wseas transctions on computers (2015),p 3.
[18] C.Omprakash, N.Devassy, N.Shushma, C.Raja and P .Mirajkar: Stroke lesion detection in MRI Images- a survey paper: Asian Journal of Applied Science and Technology (2017), p2.
[19] N.Guptal and A.Mittal: Brain ischemic stroke segmentation: a survey: Journal of Multi Disciplinary Engineering Technologies (2014),p2.
[20] A.Mouelhi, M.Sayadi, F.Fnaiech, k.Mrad and K.B.Romdhane: automatic image segmentation of nuclear stained breast tissue sections using color active model and an improved watershed method: Biomedical Signal Processing and Control, (2013),p 10.

★★★