HISTOPATHOLOGY OF PANCREATIC ISLET IN AGEING RATS BY INJECTING INTRAVENOUSLY HUMAN WHARTON'S JELLY MESENCHYMAL STEM CELL

[1]WINING ASTINI, [2]ALIF IMAN FITRIANTO, [3]ADISTI DWIJAYANTI, [4]FRANS DHYANAGIRI SUYATNA, [5]ADI WINARTO, [6]ARIEF BOEDIONO

[1,2,5,6] Department of Anatomy, Physiology, and Pharmacology, Faculty of Veterinary Medicine, Bogor Agricultural University, Bogor, Indonesia
[3]Department of Medical Pharmacy, Faculty of Medicine Universitas Indonesia, Jakarta, Indonesia
[4]Department of Pharmacology and Therapeutics, Faculty of Medicine, Universitas Indonesia, Jakarta, Indonesia
Email: [1]wining1012@gmail.com,[2]aliefiman@gmail.com[3]adisti.dwijayanti@ui.ac.id,[4]fransdsuyatna@yahoo.com, [5]katanablack704@gmail.com, [6]aboedi@yahoo.com

Abstract - The aimed of the experiment was to know the effect of wharton's jelly mesenchymal stem cells by injecting intravenously in ageing rats. This study used 6 ageing male rats model which had been 24 months old. The experiment consists of two treatment groups. The control group (A) that received NaCl (0.9%) 0,4 mL and group treatment (B) received 5 x 10^6 cells/kg of wharton's jelly mesenchymal stem cells were injected 4 times with the interval in 3 months. The end of the experiment (12 months), the rats were anesthetized and sacrified. The pancreatic tissues were collected to examine the pancreatic islets by histopathology studies. Changes of the pancreatic islet histological structure in control and treated groups ($P<0.05$) were examined using hematoxylin and eosin staining. These findings conclude that whartons jelly mesenchymal stem cell group have significant differences in terms diameter, perimeter, and area of langerhans than the control group.

Keywords - Ageing, Cell, Pancreatic, Rat, Stem

I. INTRODUCTON

Indonesia is one of the largest countries in the world. It has the proportion of elderly people who have been increasing for at least two decades and willincrease about 19.5 million by the year 2020. Ageing is one of a factor which increases population the elderly people significantly [1]. Ageing can be accelerated by diabetes disease [2]. Diabetes mellitus is caused by decreasing of pancreatic function to secrete insulin and to metabolize glucose [3]. It increases the risk to be diabetes mellitus type II [4]. Diabetes mellitus type II is associated with the decrease of β cell mass and function of the pancreatic [5]and increase related the age [3]. Injection of insulin hormone and giving sulfonylurea per oral are the treatment to overcome diabetes, but it has the weakness.According study in Massachusettes, 33% patient refused to insulin hormone and the other (40%) said that it gives the pain feeling [6].So, it needed to find the effective way to repair β cell mass and function of the pancreatic [7]. Recent studies said that wharton's jelly mesenchymal stem cell (WJ-MSCs) had the excellent properties, for example multipotent, capable of differentiating and has high proliferation properties [8]. Stem cell is one of the potential therapy to overcome the diabetes problem [9]. The purpose of this study was to know the effect and the histopathology pancreatic islet by injecting intravenously of human wharton's jelly mesenchymal stem cells in ageing rats.

II. MATERIAL AND METHOD

2.1. Experimental animals

Male 24 months old Sprague-Dawley (SD) rat (n=6), were purchased from Veterinary Medicine Laboratory Animal Bogor Agricultural University (UPHL). This study was approved by Animal Care and Use Committee (ACUC) Veterinary Hospital of Bogor Agricultural University, Indonesia (license: 21-2016 ACUC RSHP FKH-IPB).All rats were maintained on a 12h light cycle in the laboratory. They were given feed and drinking water ad libitum.

2.2. Preparation and administration of hWJ-MSCs

Human wharton's jelly mesenchymal stem cell (hWJ-MSCs) was derived from human umbilical cords (UC). The preparation used women's fresh UC after normal vaginal delivery. The women were 25-40 years old. This administration was approved by the Institutional Ethics Committee at the Stem Cell and Cancer Institute, Jakarta, Indonesia and from the Institutional Ethics Committee collaboration between Maranatha Christian University, Bandung, Indonesia and Immanuel Hospital Bandung, Bandung, Indonesia. The method of cell culture, identification of biological properties and the experimental protocols of hWJ-MSC followed with the same procedures which were previously described[10].

2.3. Transplantation of hWJ-MSCs into ageing rats

The experiment consists of two treatment groups. The control group (A) that received NaCl (0.9%) 0,4 mL and group treatment (B) received 5 x 10^6 cells/kg of human wharton's jelly mesenchymal stem cells were injected 4 times with the interval in 3 months. All rats

were injected intravenously. The end of the experiment (12 months), the rats were anesthetized and sacrified for further analyses.

2.4. Hematoxylin and eosin staining

All rats were anesthetizedwith a combination of ketamine and xylazine ratio (1: 2), a dose of 0.1 ml /kg body weight intraperitoneally and the pancreatic were removed and fixed with paraformaldehid 4%. The samples embedded paraffin and sectioned at 3 πm thickness by sledge microtome. The staining of hematoxylin and eosin referred to the [11].

2.5. Histopathology analysis

Histophatology studies were carried out on rat pancreatic by using ImageJ software and by Olympus CX31 light microscope (Olympus, Tokyo, Japan. The diameters, perimeter, and area of langerhans were quantified in the tissue sections. Results had been represented in micrometer and compared with control.

2.6. Statistical analysis

The data were performed using the SPSS statistical package (SPSS version 20). Data were analyzed by t-test. P values less than 0.05 was considered to be statistically significant.

III. RESULT AND DISCUSSION

Injecting intravenously of human wharton's jelly mesenchymal stem cells in ageing rats had a significant effect on the average diameter, area and perimeter in pancreatic islet (P > 0.05). There was a difference between group A which injected with NaCl (0.9%) 0,4 mL (control) and group treatment (B) which injected with dose 5 x 10^6 cells/kg of wharton's jelly mesenchymal stem cells. The pancreatic diameter measurement results for control and treatment could be seen in Figure 1. The diameter average graph showed that pancreatic diameter in thetreatment group (WJ-MSCs) had a greater number than the control. On the other hand, the area number of WJ-MSCs was greater than the control. It could be seen in figure 2. The value of perimeter WJ-MSCs was line with diameter and area of pancreatic islet.

Hematoxylin and eosin staining showed a reduction of diameter, area,and perimeter in control. Injecting intravenously of human wharton's jelly mesenchymal stem cells showed that there was theimprovement in diameter, area, and perimeter. It's shape was well-outlined boundaries (figure 4).

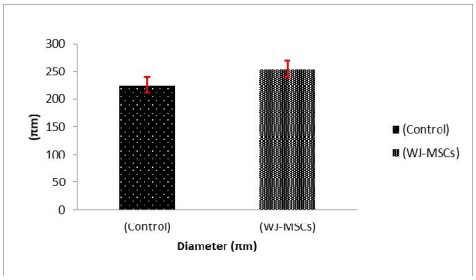

Figure 1Diameter average graph, group control and group WJ MSCs (5 x 10^6 cells/kg). Note:* (P>0.05), n = 6

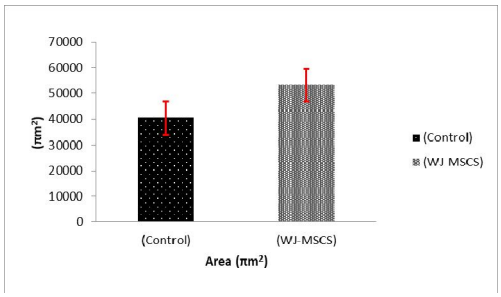

Figure 2Area average graph, group control and group WJ MSCs (5 x 10^6 cells/kg). Note:* (P>0.05), n = 6

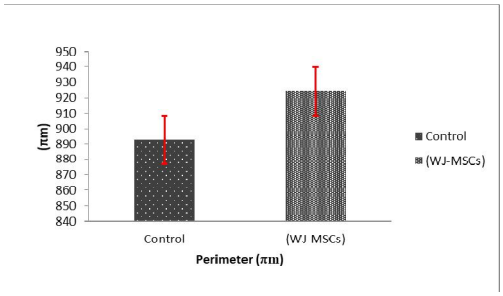

Figure 3Perimeter average graph, group control and group WJ MSCs (5 x 10^6 cells/kg). Note:* (P>0.05), n = 6

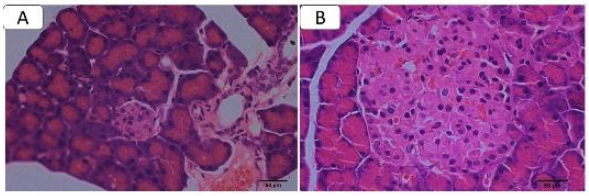

Figure4 (A) Histology of pancreatic in control group, (B) Histology of pancreatic in the treatment group, by using hematoxylin and eosin staining. Magnification: 40x; Scale bar: 50 πm.

Ageing caused insulin secretory dysfunction and the high glucose intolerance in elder people. Ageing also effected pancreatic cell function[12]. It increased the prevalence of type 2 diabetes related with age in the elder population [13]. In our research, treatment of ageing rat by injecting hWJ-MSCs resulted in considerable to increase the diameter, area, and perimeter the pancreatic islet. This result indicates that injecting hWJ-MSCs intravenouslyhas the potency to be a treatmentfor type 2 diabetes related to age in the elder population. Many recent studies said that ageing caused pancreatic changes. It increased chonic inflammatory status and triggered altered functional plasticity in pancreatic islet[14]. On the other studies said that islet pancreatic from aged mice were more sensitive to endoplasmic reticulum stress than young mice. This is related to the reduction of insulin and apoptosis in the pancreatic islets of type II diabetes. The protein CHOP (CCAAT-enhancer-binding protein homologous protein) is the major factor which causes apoptosis and endoplasmic reticulum stress and beta cell destruction [15].So, It is important to find the best treatment to repair the apoptosis islet pancreatic which is caused by ageing. One of the best treatment is transplantation wharton's

jelly mesenchymal stem cell intravenously. The wharton's jelly mesenchymal stem cellis a stromal population. International Society for Cellular Therapy says that wharton's jelly has characteristics of mesenchymal stem cell, for example, growing as adherent cells with mesenchymal morphology, self-renewing, expressing cell surface markers displayed by MSCs, and can be differentiated into bone, cartilage, adipose, muscle, and neural cells.Wharton's jelly has thebetter expansion, faster growht in vitro and can synthesize different cytokines.In some preclinical animal, wharton's jelly is used to be therapeutic, such as as neurodegenerative disease, cancer, heart disease and diabetes[16].

Inthe diabetic trials studies, hypothesized that injecting intravenously of human wharton's jelly mesenchymal stem cells could regenerate pancreatic in animals with type1 DM and increase islets number, area, and diameter of pancreatic [17]. In this study,we try to use ageing rats as an experimental model. Our results conclude thatinjecting intravenously of human wharton's jelly mesenchymal stem cells can improve the number of diameter, perimeter,and area of langerhans. This histomorphometric analysis confirmed that hWJ-MSCs has potencyto home and to regenerate the pancreatic islet in ageing rat.

CONCLUSION

The conclusion from this study show that injecting human wharton's jelly mesenchymal stem cell intravenously can successfully improve the number of diameter, perimeter and area of langerhans in ageing rat. Human wharton's jelly mesenchymal stem cell has potency to be regenerative medicine treatment in ageing case.

ACKNOWLEDGMENTS

The authors gratefully acknowledge the financial support from LPDP (Lembaga Pengelola Dana Pendidikan).

REFERENCES

[1] Adlakha A, Rudolph DJ. 1994. Aging trends : Indonesia. Cross-Cultural Gerontology. 9:99-108.

[2] Mazza AD, Morley JE. Update on diabetes in the elderly and the application of current therapeutics. J Am Med Dir Assoc 2007;8:489–92.

[3] Cuesta S, Kireev R, Garcı´a C, Rancan L, Vara E, Tresguerres JA. 2013. Melatonin can improve insulin resistance and aging-induced pancreas alterations in senescence accelerated prone male mice (SAMP8). Age. 35:659–671.

[4] Monickaraj F, Aravind S, Gokulakrishnan K, Sathishkumar C, Prabu D, Mohan V, Balasubramanyam M. 2012. Accelerated aging as evidenced by increased telomere shortening and mitochondrial DNA depletion in patients with type 2 diabetes. Mol Cell Biochem. 365:343–350.

[5] Weir GC, Bonner-Weir S. 2013. Islet b cell mass in diabetes and how it relates to function, birth, and death. N Y Acad. Sci. 1281:92–105.

[6] Larkin M, Capasso V, Chen C, Mahoney E, Hazard B, Cagliero E, Nathan D. 2008. Measuring psychological insulin resistance: Barriers to insulin use. DiabetesEducator. 34(3)511-517

[7] Jung KY, Kim KM and Lim S. 2014. Therapeutic approaches for preserving or restoring pancreatic β-cell function and mass. Diabetes Metabolism. 36:426-436.

[8] Halim D, Murti H, Sandra F, Boediono A, Djuwantono T dan Setiawan B. 2010. Stem Cell Dasar Teori dan Aplikasi Klinis. Jakarta (ID): Erlangga Pr.

[9] Guo T, Hebrok M. 2009. Stem cells to pancreatic beta-cells: new sources for diabetes cell therapy. Endocrine. 30:214–27.

[10] Widowati W, Wijaya L, Bachtiar I, et al. Effect of oxygen tension on proliferation and characteristics of Wharton's jelly-derived mesenchymal stem cells. Biomarkers Genomic Med. 2014;6:43e48

[11] Kiernan JA. 1990. Histological & Histochemical Methods: Theory and Practice. 2nd ed. Oxford (IO): Pergamon Pr

[12] Adelman R. 1989. Secretion of insulin during aging. J Am Geriatr Soc. 37: 983–990.

[13] Halter JB. 1995. Carbohydrate metabolism. Am. Physiol. Soc. 119–145.

[14] Sandovici I, Hammerle CM, Cooper WN, Smith NH, Tarry-Adkins JL, Dunmore BJ, Bauer J, Andrews SR, Yeo GSH, Ozanne SE, ConstânciaM. 2016. Ageing is associated with molecular signatures of inflammation and type 2 diabetes in rat pancreatic islets. Diabetologia. 59 (3): 502-511.

[15] Puthalakath H, O'Reilly LA, Gunn P, Lee L, Kelly PN, Huntington ND. 2007. ER Stress triggers apoptosis by activating BH3-only protein bim. Cell. 129: 1337–1349

[16] Troyer DL, Weiss ML. Wharton's jelly-derived celss are a primitive stromal cell population. Stem Cells. 26:591-9

[17] El-Hossary N, Hassanein H, El-Ghareeb AW, Issa H. 2016. Intravenous vs intraperitoneal transplantation of umbilical cord mesenchymal stem cells from Wharton's jelly in the treatment of streptozotocin induced diabetic rats. Diabetes Reseach and Clinical Practice. 121:102-111.

★★★