COLOR MAPPED 3D SHAPE VISUALIZATION FOR BRAIN HIPPOCAMPUS IMAGES

[1]HEUNG-KOOK CHOI, [2]BOO-KYEONG CHOI, [3]JAE-HONG SO, [4]NUWAN MADUSANKA

[1,2,3,4] Department of Computer Engineering, u-AHRC, Inje University, Korea
[1]Center for Image Analysis, Uppsala University, Sweden
E-mail: [1]cschk@inje.ac.kr, [2]kscript7258@daum.net, [3]tmsmsor777@naver.com, [4]nuwanmadusanka@hotmail.com

Abstract - In this paper we presented a color mapping according to the hippocampus shape of brain MR images. Many researchers have been doing quantitative analysis of hippocampus during the late period. When the clinician reads out the MR image promptly and diagnoses it, the shape of the color mapping hippocampus is required. Conventionally the medical color images were visualized according to the brightness/intensity. However, we performed a new color mapping by two methods in this study. First, looking at the central axis of the hippocampus, from this, we found the edge pixels where the vertical plane meets, and performed color mapping according to the distance from the center axis. In the second, we found the head and tail of the hippocampus and drew a line, and the distance from the line to the edge of the vertical plane was calculated and mapped into color. Finally, the color visualization of hippocampus was obtained in good results. If it is used in clinical practice, it can be used easily and precisely because it can see the exactly shape of hippocampus at a glance.

Index Terms - Color mapping, 3D shape, hippocampus, MRI images, quantitative analysis, visualization

I. INTRODUCTION

Dementia is a common and growing problem, affecting 5% of the over 65s and 20% of the over 80s. The recent availability of new treatments for dementia has renewed interest in the use of brain imaging techniques that can assist in the accurate recognition of Alzheimer's disease (AD), dementia with Lewy bodies (DLB), vascular dementia (VaD) and front temporal dementia (FTD) [1]. It was first described by German psychiatrist and neuropathologist Alois Alzheimer in 1906 and was named after him [2]. Most often, AD is diagnosed in people over 65 years of age [3] although the less-prevalent early-onset Alzheimer's can occur much earlier. In 2006, there were 26.6 million people worldwide with AD [4]. In order to detect early AD, the anatomy of hippocampus, which is the part of the brain that is involved in memory forming, organizing, and storing, is needed to be obtained from whole brain image. The hippocampus is a significant element in human memory due to its important role in forming, organizing, and storing memories. Hippocampal damage can result in anterograde amnesia, which is due to a reduction in its ability to work properly; damage can lead to a significant loss of neurons as the severity of disease progresses, such as in Alzheimer's disease (AD) and Parkinson's disease (PD). In magnetic resonance imaging (MRI), the intensity values of the hippocampus area are very similar to, and difficult to distinguish from other tissues located around it.

Therefore the image segmentation is significant role. Yang et al. [5] presented a segmentation algorithm by observing the location of neighboring structures and shapes that provided configurations to aid in the segmentation process. Benjelloun et al. [6] measured the distances between the mean value, and observed values of the image using Mahalanobis distances. Chan and Vese [7] proposed an active contour model to segment an object without using an image gradient. However the hippocampus has diversities for shape and volume. For the reasons we implemented and visualized the diversity hippocampus by color mapping as distance from center point and top from end axis. This his paper is organized as follows. In Section II, we describe the used image materials and proposed method. Section III presents the color visualizing implementation and results demonstrating the effectiveness of the method. Section IV provides our implementations both advantages and disadvantages and section V concluded our paper finally.

II. MATERIALS AND METHODS

A. MR Image Acquisitions

Participants were recruited from a larger cohort of living subjects enrolled in the Chosun National University, National Dementia research center to investigate dementia study within the Republic of Korea. All enrolled subjects undergo a clinical and informant-based interview, a comprehensive cognitive assessment including, physical examination, MRI brain scan and blood-screening tests as part of the scheduled protocol for diagnostic purposes. Potential participants for the current prospective study were randomly selected from the participant database according to clinical diagnosis. General inclusion criteria applicable to all subjects for this sub-study, were 60 years of age or older. The MR images used in this paper are obtained from the the Chosun National University, National dementia research center. The MRI scans are acquired using 1.5 Tesla, T1-weighted by Siemens scanner with

TE/TI/TR = 2.98/900/2300 ms, slice thickness = 0.8 mm, Rows × Cols × Slices = 320 × 320 × 240, and voxel size of 0.8 × 0.8 × 0.8 mm3. We acquired 58 subjects which are shown in the Table 1.

Cognitive Status	Numbers	Age	Sex(f/m)
AD	19	71.3 ± 2.9	10/9
MCI	19	69.5 ± 3.0	10/9
NC	20	69.5 ± 3.0	10/10

Table 1: MR characteristic images for the categorized participants to our study

(The data are presented in the format mean ± standard deviation. AD = Alzheimer's disease patients, MCI = mild cognitive impairments, NC = normal controls.) MRI raw data input our image processing system. The brain hippocampus segmentation was accessed by the manual drawing the object and using active shape modeling. Then one of them was selected to calculate the distance from the center axis to edge object. Finally we performed the color mapping according to the distance. Then the shape was visualized totally. The whole process has shown in the Fig. 1.

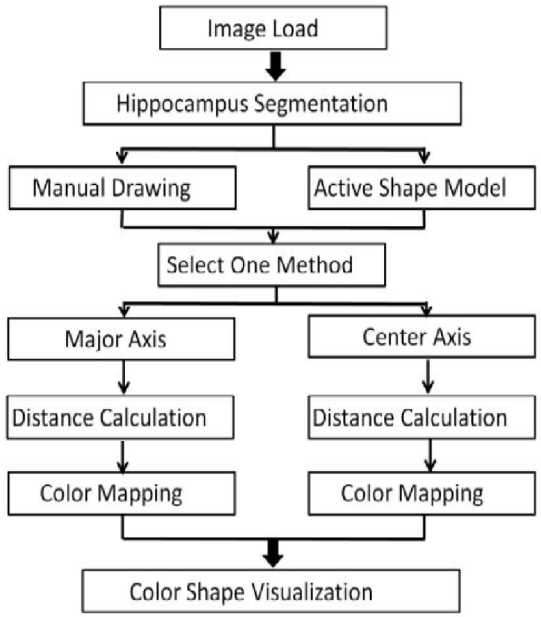

Fig. 2 – The whole working process for the color shape visualization for the MRI brain hippocampus.

B. Manual Drawing the Hippocampus

In the sagittal image provided by the MR image, our two experts extracted the hippocampus individually [8]. Therefore, the minor differences according to experts should be considered. This is a time-consuming task. However, this is true because it is often used to the ground truth.

The figure below shows the step by step drawing extraction of hippocampus. The original image with initial curve is shown in (a), then the intermediate to final steps are shown in (b) to (d) in Fig. 2.

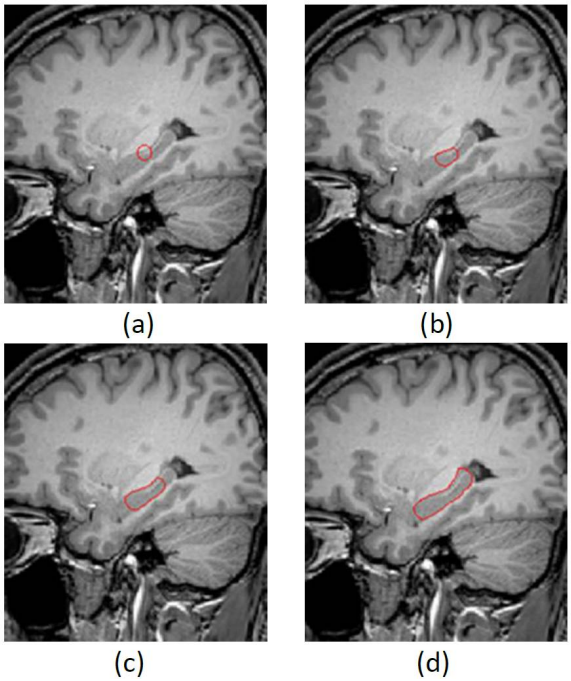

Fig. 2 - Four steps for the hippocampus extraction on MR images. The initial to final steps are shown from (a) to (d).

C. Implementation Active Shape Model(ASM)

The goal of this step is to make a training set consisting of hippocampus shapes which are expressed by the coordinate of markers. This is the most time-consuming process of ASM because of the manual placement of markers. In our hippocampus case, we put 11 markers on the hippocampus [9].

The order of marker is shown in Fig. 3. The markers were put on the most important and distinguishable parts of object, e.g. corner, curve, etc. Even though 11 markers have been put on the most important parts of object, they still cannot represent the actual shape of hippocampus. Therefore, we put more markers between existing markers automatically using interpolation. The goal of this interpolation process was not only to get better shape of hippocampus, but also to observe the effect of marker numbers in the ASM segmentation.

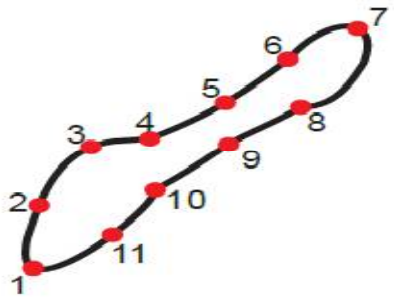

Fig. 3 – Hippocampus shape extraction by the order of markers placement on hippocampus.

In this paper, we propose two methods to more precisely measure the contraction of the hippocampus. The proposed method is based on the measurement of a new center point using the axis and center of gravity of the hippocampus. To use the two methods, the sagittal plane of the MR image must be configured as a coronal plane. That is the why the re-slice work was needed. We measured the distance between the marked points and the edge of the hippocampus, and implemented the software to intuitively identify and analyze hippocampal deformations by changing the color according to the distance. The results of this method can be confirmed by rendering the hippocampus and the longest straight line drawn through Fig. 4 (a) and Fig. 4 (b) together.

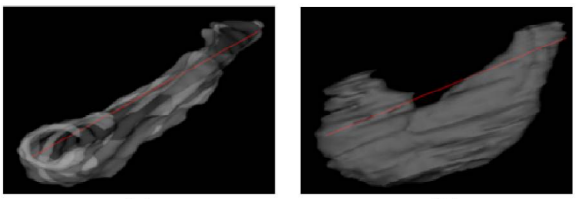

Fig. 4 – (a) Top and (b) side projection of the extracted hippocampus with the straight red line from top to end.

The first proposed method finds and displays the hippocampus' longest axis from the data rendered in 3D. Then, the data composed of sagittal is re-sliced into Coronal and the hippocampus's longest axis is displayed for each slice. Then, the distance from the edge was calculated, and the color of each slice edge was changed according to the distance. Then, it is rendered in 3D and color mapping is performed. The second method re-slices the data composed of three-dimensional three-sided sagittal planes into coronal planes. To find the center of gravity of each rehabilitated hippocampal image, calculate the distance between the center of gravity and the edge, and change the color of the edge of each slice according to the distance. Then, it is rendered in three dimensions to perform three-dimensional color mapping. We implemented two proposed methodologies and verified objectivity and effectiveness through visualization.

III. RESULTS

In this paper, Intel Core i5 CPU-6500, CPU 3.20GHz and Geforce 770 graphics card were used as the development environment. MR images obtained from Chosun University were obtained from 27 patients with 3D MR images (Alzheimer's Disease (AD), Mild Cognitive Impairment (MCI), and Normal Control (NC) were used. There are 240 slices in each 3D image, and the 2D size is 256x256. Software development uses Visual Studio 2015, and the authoring program is based on the C # language and consists of .Net Framework 4.2 Windows Application. Furthermore, Open CV-3.2.0, Insight Toolkit (ITK)-4.11, and VTK (Visualization Tool Kit)-7.1 were used for the additional libraries.

Fig. 5, Fig. 6 and Fig. 7 are the 3D visualization of the results to generate by the flowchart and the proposed method. First, we used the VtkMarchingcubes method provided by the VTK library in the process of rendering object in 3D. We also used the VtkLookuptable method provided by the VTK library to perform color mapping on the rendered 3D object. Fig. 5 (a), Fig. 6 (a) and Fig. 7 (a) represents each AD, MCI, and NC in order and finds the longest axis in the hippocampus and calculates the distance to the edge using the axis. It is the result of 3D visualization by mapping different colors according to distance. Fig. 5 (b), Fig. 6 (b) and Fig. 7 (b) represent AD, MCI, and NC, respectively, in order. The three-dimensional rendered hippocampus was re-sliced to find the center of each slice, and the distances to the edges were calculated. The result was 3D visualization by mapping of the different colors according to distance.

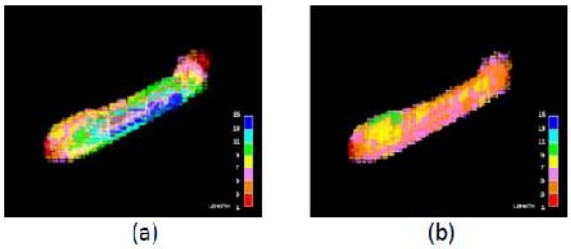

Fig. 5 - 3D Visualization result for AD patient: (a) using Shaft and (b) using center point.

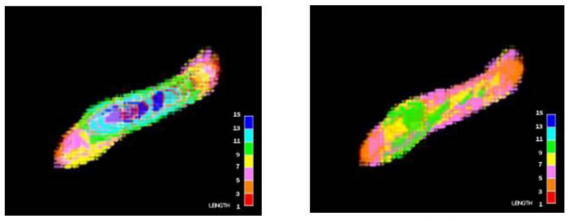

Fig. 6 - 3D visualization result for MCI Patient: (a) using shaft and (b) using center point.

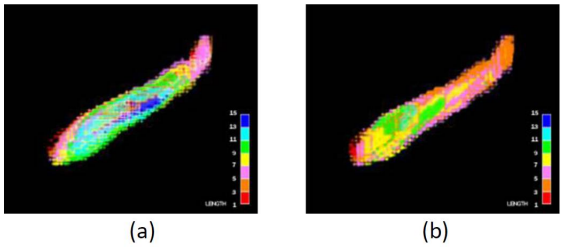

Fig. 7 – 3D visualization result for normal control: (a) using Shaft and (b) using Center Point.

IV. DISCUSSION

Actually color mapping is a function that maps (transforms) the colors of one (source) image to the colors of another (target) image. A color mapping

may be referred to as the algorithm that results in the mapping function or the algorithm that transforms the image colors. Color mapping is also sometimes called color transfer or, when grayscale grayscale images are involved, brightness transfer function (BTF) [10]. Generally, the color mapping in medical images has been progressed according to brightness [11].Therefore, it was possible to analyze morphologically as the color according to the pixel value alone. Many techniques have been proposed to perform color segmentation [12-14]. A popular technique is based on clustering pixels in a color model.

The hippocampus of the brain has been calculated as volume or area as a quantitative analysis. In this study, it is possible to see the shape change of the hippocampus in three dimensions newly. Therefore, it is possible to read-out images intuitively by the color mapping of the irregular changing hippocampus. The color table was represented only in seven colors, so that the surface of the hippocampus did not appear smooth in the Fig. 5, Fig. 6, and Fig. 7.

In AD, it was more widely distributed in color than in NC. It can be seen that the shape change in AD is much more visible. This is a big difference from the quantitative analysis by volume or surface area. This will be solved by increasing the number of colors. The color mapped images will be useful in clinical practice in the future.

CONCLUSION

In order to accurately and objectively measure hippocampal contraction or thinning, quantitative analysis of what part of the hippocampus has occurred is indispensable and important for the diagnosis and prognosis of Alzheimer's Disease (AD), Mild Cognitive Impairment (MCI), and Normal Control (NC). Therefore, we developed a more quantitative analysis and analysis tool by performing automatic color mapping according to the degree of deformation at the center of gravity of the hippocampus. In the future we are going to do an attempt a color image analysis for the brain MRI hippocampus.

ACKNOWLEDGEMENTS

This research was supported by Uppsala University Fund for the invited guest researcher (202100-2932). This research was also supported by Basic Science Research Program through the National Research Foundation of Korea(NRF) funded by the Ministry of Education (2015-059319).

REFERENCES

[1] J.T. O'Brien and D.M. Frcpsych, “Role of Imaging Techniques in the Diagnosis of Dementia,” British Journal of Radiology, vol. 80, no. 2, pp. 1-7, 2007. (https://doi.org/10.1259/bjr/33117326)

[2] N.C. Berchtold, and C.W. Cotman, “Evolution in the Conceptualization of Dementia and Alzheimer's disease: Greco-Roman period to the 1960s”, Neurobiology Aging, May-Jun vol. 19, no. 3, pp.173-89, 1998.

[3] R. Brookmeyer, S. Gray, C. Kawas, “Projections of Alzheimer's Disease in the United States and the Public Health Impact of Delaying Disease Onset,” American Journal of Public Health. vol. 88, no. 9, pp. 1337–42, 1998.

[4] R. Brookmeyer, E. Johnson, K. Ziegler-Graham , M.H. Arrighi, “Forecasting the Global Burden of Alzheimer's Disease,” Alzheimer's and Dementia, vol. 3, no. 3, pp. 186–191, 2007.

[5] J. Yang, L.H. Staib and J.S. Duncan, “Neighbor-constrained Segmentation with Level Set based 3D Deformable Models,” IEEE Transactions on Medical Image, vol. 23, no. 8, pp. 940-948, 2004.

[6] M. Benjelloun, S. Mahmoudi and F. Lecron, “A Framework of Vertebral Segmentation Using the Active Shape Model-based Approach,” International Journal of Biomedical Imaging, vol. 2011, no. 9, pp. 1-14, 2011.

[7] T. Chan and L. Vese, “Active Contour without Edges,” IEEE Transactions on Image Processing, vol. 10, pp. 266-277, 2001.

[8] Y.S.. Izmantoko, .H.S. Yoon, E. Adiya, C.W. Mun, Y. Hu, H.K. Choi, “Implementation of 2D Active Shape Model-based Segmentation on Hippocampus.,” Journal of Korea Multimedia Society, bol.17, no.1, pp.1-7, 2014.

[9] B. Vongphachanh, H.K. Choi, “Comparison of Level Set-based Active Contour Models on Subcortical Image Segmentation,” Journal of Korea Multimedia Society, vol. 18, no. 7, pp. 827-833, 2015.

[10] Color mapping, from Wikipedia, https://en.wikipedia.org/ wiki/Color_mapping, (in access 2017.10.20).

[11] H.J. Choi, I.H. Choi, N.N. Cho, H.K. Choi, “Color Image Analysis for Quantifying Renal Tumor Angiogenesis,” Analytical and Quantitative Cytology and Histology, vol. 27, no. 1, pp. 43-51, 2005.

[12] X.Yang, T. Wang and J. Bu, “Color Image segmentation Using Pixel Wise Support Vector Machine Classification”, Pattern Recognition, vol. 44, no. 4, pp. 777-787, 2011.

[13] R. Huang, N. Sang, D. Luo, Q. Tang, “Image segmentation via coherent clustering in L*a*b* color model”, Pattern Recognition Letters, vol. 32, no. 7, pp. 891-902, 2011.

[14] N. Kehtarnavaz, J. Monaco, J. Nimtschek, A.Weeks, “Color Image Segmentation Using Multi-scale Clustering”, IEEE Southwest Symposium on Image Analysis and Interpretation, pp. 142-147, 1998.

★★★